

# Treatment of laryngeal paralysis in captive wild felids; Arytenoid lateralization technique

Phingphol Charoonrut<sup>1\*</sup>, Sukanya Manee-in<sup>1</sup>, Ruangrat Buddhirongawat<sup>1</sup>,  
Siriporn Tangsudjai<sup>1</sup>, Nareerat Sungchachai<sup>1</sup>, Tipapan Parnluck<sup>2</sup>, Luxsana Pasittichai<sup>3</sup>

<sup>1</sup>Faculty of Veterinary Science, Mahidol University, Nakhon Prathom 73170

<sup>2</sup>Bueng Chawak Zoo, Supanburi 72120

<sup>3</sup>Kao-Pratapchang Wildlife Breeding Center, Rachaburi 70150

\*Corresponding author, E-mail address: vsper@mahidol.ac.th

## Abstract

The purpose of this study was an evaluation of the result of laryngeal paralysis treatment in tigers (*Panthera tigris*) and lions (*Panthera leo*) by using arytenoid lateralization technique. Four tigers with left unilateral laryngeal paralysis, 2 tigers and 2 lion with bilateral laryngeal paralysis were included. The surgical procedure was performed by left unilateral arytenoid lateralization in all animals. The better clinical signs after operation were shown in 7 animals except 1 lion that was not improved and died 14 days after operation because of pre-operative systemic infection. One tiger died with the recurrent problem at 10 days after operation because of the laceration at the muscular process of arytenoid cartilage at prosthesis anchored. This technique used in this study can be used to treat the laryngeal paralysis in tigers and lions.

**Keywords:** arytenoid lateralization; laryngeal paralysis; lion; tiger; wild felids

# การรักษาปัญหากล่องเสียงอัมพาตในสัตว์ตระกูลเสือดาววิธี

## Arytenoid lateralization technique

พิงพล จรูญรัตน์<sup>1\*</sup> สุกัญญา มณีอินทร์<sup>1</sup> รวงรัตน์ พุทธิรงค์วัตร<sup>1</sup> ศิริพร ตั้งสุดใจ<sup>1</sup>  
นารีรัตน์ สังขละไชย<sup>1</sup> ทิพาพรรณ ปานลักษณ์<sup>2</sup> ลักษณา ประสิทธิ์ชัย<sup>3</sup>

<sup>1</sup>คณะสัตวแพทยศาสตร์ มหาวิทยาลัยมหิดล อ.พุทธมณฑล จ.นครปฐม 73170

<sup>2</sup>สวนสัตว์บึงฉวาก จ.สุพรรณบุรี 72120

<sup>3</sup>สถานีเพาะเลี้ยงสัตว์ป่าเขาประทับช้าง จ.ราชบุรี 70150

\*ผู้รับผิดชอบบทความ E-mail address: vspcr@mahidol.ac.th

### บทคัดย่อ

วัตถุประสงค์ของการศึกษานี้เพื่อประเมินผลของการรักษาปัญหากล่องเสียงอัมพาตในเสือดาวและสิงโต ด้วยวิธีการเย็บรั้ง ด้านข้างที่กระดูกอ่อนริทีนอยด์ โดยทำการรักษาเสือดาวที่มีปัญหากล่องเสียงอัมพาตข้างซ้ายจำนวน 4 ตัว เสือดาวจำนวน 2 ตัว และสิงโตจำนวน 2 ตัวที่มีปัญหากล่องเสียงอัมพาตทั้งซ้ายและขวา ทำการเย็บรั้งด้านข้างของกระดูกอ่อนริทีนอยด์ทางด้านซ้ายในสัตว์ป่วยทุกตัว หลังการผ่าตัดสัตว์ป่วย 7 ตัวมีอาการดีขึ้น ยกเว้นสิงโตเพียงตัวเดียวที่อาการไม่ดีขึ้นและตายหลังจากผ่าตัดไปแล้ว 14 วัน เนื่องจากภาวะติดเชื้อในร่างกายก่อนการผ่าตัด พบเสือดาว 1 ตัวตายหลังผ่าตัดไปแล้ว 10 วัน จากการเกิดซ้ำของปัญหากล่องเสียงอัมพาตเนื่องจากมีการฉีกขาดของ muscular process ของกระดูกอ่อนริทีนอยด์ซึ่งเป็นบริเวณที่มีการเย็บรั้ง การศึกษานี้พบว่าวิธีการรักษาสามารถใช้ในการรักษาปัญหากล่องเสียงอัมพาตในเสือดาวและสิงโตได้

คำสำคัญ : การเย็บรั้งไปด้านข้างของกระดูกอ่อนริทีนอยด์ กล่องเสียงอัมพาต สิงโต เสือดาว สัตว์ตระกูลเสือดาว

## Introduction

Laryngeal paralysis is an abnormal function of the larynx, caused by partial or complete in abduction of arythenoid cartilages and vocal folds during inspiration (Hedlund, 2007). Common clinical signs such as increase inspiratory noise, inspiratory stridor, exercise intolerance, cough and aspiration pneumonia are presented. It can be severe, especially when exercise or over excited. Laryngeal paralysis may cause by trauma of cervical region, in which recurrent laryngeal nerve are damaged. It may be occurred by iatrogenic cause after surgery (e.g. tracheal collapse and thyroidectomy), cervical or thoracic mass, congenital and idiopathic causes (Hedlund, 2007; Hardie et al., 2009). For surgical treatment, previous studies in dog, cat and horse demonstrated various surgical methods such as arytenoid lateralization, ventriculectomy, vocal cordectomy, partial laryngectomy, castellated laryngofissure, sacculotomy and neuromuscular pedicle graft (Stick et al., 1999; Hedlund, 2007), although the treatment of choice is arytenoid lateralization (tie-back). The retrospective study in cat showed the good response after unilateral arytenoids lateralization was performed (Hardie et al., 2009; Thunberg and Lantz, 2010). Until the present, the case report and treatments of laryngeal paralysis in wild felids such as tiger or lion in captive environment have never been done. Therefore, this study aims to observe the results after laryngeal paralysis correction by using arytenoid lateralization in tiger and lion.

## Materials and methods

The present study was approved by The Faculty of Veterinary Science- Animal Care and Use Committee (FVS-ACUC) Mahidol University, the protocol No. MUVS-2011-33, protocol title "Treatment of laryngeal paralysis in wild felids: Arytenoid Lateralization".

## Animals

In total, six tigers (*Panthera tigris*) and 2 lions (*Panthera leo*) were included. The 4 captive breed tigers were obtained from captive breed at Kao-Pratabchang Wildlife Breeding Center, 1 tiger from Kao-Son Wildlife Breeding Center, which belongs to Department of National Park, Wildlife and Plant Conservation. Another tiger and 2 captive breed lions were obtained from Bueng Chawak Zoo. Blood samples were collected during anesthesia. The complete blood count (CBC) and serum biochemistry (BUN, creatinine, ALP, ALT, AST, CK and total protein) were evaluated. All animals have moderate to severe inspiratory stridor or dyspnea, increase inspiratory noise or wheezing, exercise intolerance, loss of appetite. Antibiotics and non-steroidal anti-inflammatory drugs (NSAIDs) were given in 4 tigers and 1 lion before surgical treatment but incurable.

## General anesthesia

All animals were anesthetized with a combination of xylazine hydrochloride (1mg/kg) (Ilium xylazil-100®, Troy laboratories Pty.Ltd., Australia), atropine sulphate (0.04 mg/kg) (Atropine®, T.P.drug laboratory Ltd., Thailand) and ketamine hydrochloride (4 mg/kg) (Ketamil®, Troy laboratories Pty.Ltd., Australia) by using blow dart. The general anesthesia was maintained with 2 % isoflurane (Terrell™, Minrad Inc., USA) in oxygen. The following procedures were performed under general anesthesia; direct laryngoscopy was done to diagnose the abnormality according to Radlinsky et al.(2009), blood collection. Enrofloxacin (Baytril®, Bayer Korea Ltd.) 5 mg/kg and single shot of 0.5 mg/kg prednisolone (Prednisolone®, T.P.drug laboratory Ltd., Thailand) and 4 mg/kg of Tolfenamic acid (Tolfedine®, Vetoquinol, France) ( extra-label used) were administered subcutaneous before operation.

### Surgical techniques

Surgical procedure was modified from Hardie et al. (Hardie et al., 2009). Briefly, surgery was performed on only the left cervical area of all animals. The surgical incision was done over the dorsolateral aspect of the larynx just ventral to the jugular vein, beginning at the caudal angle of the mandible to 3 to 4 cm caudal to the larynx. Thyropharyngeus muscle was transected (Fig. 1) to expose cricoids cartilage and arytenoids cartilage. The lateralization procedure was performed by using polyamide (ETHILON®) No. 2. In all animals, two lateralization interrupted sutures were placed between dorsolateral aspect of cricoid cartilage (Fig. 2) and muscular process of arytenoids cartilage (Fig. 3). The sutures were individually tied (Fig. 4), thereafter the endotracheal tube was removed and then direct laryngoscopy was done in order to examine the appropriate abduction of arytenoid cartilage. Enrofloxacin 5 mg/kg and Tolfenamic acid 4 mg/kg were administered subcutaneous after surgery until 7 days.

### Follow-up

The inspiratory sound, cough, gagging and swallowing reflex were observed in all animals for 14 days after surgery. The animals were general anesthetized to remove the skin sutures and direct laryngoscopy was performed to evaluate the outcome.

### Results


Six tigers (2 males and 4 females; mean age 4.2 years; range 2 - 10 years), No. 1-5 and 6, and 2 lions, No. 1 and 2, (1 male and 1 female; mean age 3.5 years; range 2 - 5 years) were investigated. The data of all animals were shown in Table 1. From the direct laryngoscopy and history taking, all of animals in this study were diagnosed as idiopathic laryngeal paralysis. Unilateral (left) laryngeal paralysis (Fig. 5) was identified in 5 animals (62.5%) and 3 animals had bilateral laryngeal paralysis (Fig. 6) (37.5%). For

complete blood count and serum biochemistry profiles, all of animals had normal blood profile, except Tiger No. 5 that had moderate anemia (23% PCV) and Lion No. 7 that had anemia (16% PCV) and leukocytosis (leukocyte 79,300 cell/ $\mu$ l) with slightly purulent nasal discharge and 7-10% dehydration were also observed.

Regarding the surgical procedure, surgical complication was not presented in all animals, except Lion No. 7, in which the iatrogenic perforation of the pharynx was occurred at the lateral aspect of arytenoid cartilage and then it was sutured during the surgery with simple interrupted suture by using polydioxanone (PDS® II) No. 2-0. After unilateral arytenoid lateralization, the arytenoid cartilage was more abducted resulting in increased the rima glottidis area (Fig. 7).

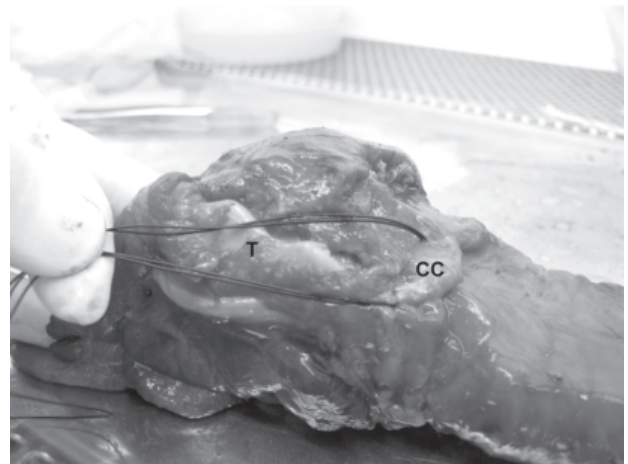### Post-surgical evaluation

All of animals in this study recovered from anesthesia without complication. Five animals (Tiger No. 2-5 and Lion No. 6) recovered from surgical treatment with minimal complication. The slightly harsh inspiratory noise was still observed. They were anesthetized for skin sutures removal and direct laryngoscopy was together performed. The arytenoids cartilages were demonstrated and located in the same position as just after operation. Tiger No. 1 showed dyspnea, inspiratory noise, depress and anorexia at day 9 after surgery and died 1 day later. The necropsy results demonstrated lung congestion and laceration of muscular process of arytenoid cartilage at prosthetic area resulting in adduction of arytenoid cartilage. Lion No. 7 recovered from surgery, the brownish exudates were found in the surgical wound at day 7 after surgery and died 2 days later, and the necropsy results showed the exudates are likely to be the gastric content. Tiger No. 8 died of aspiration pneumonia at 11 days after surgery.



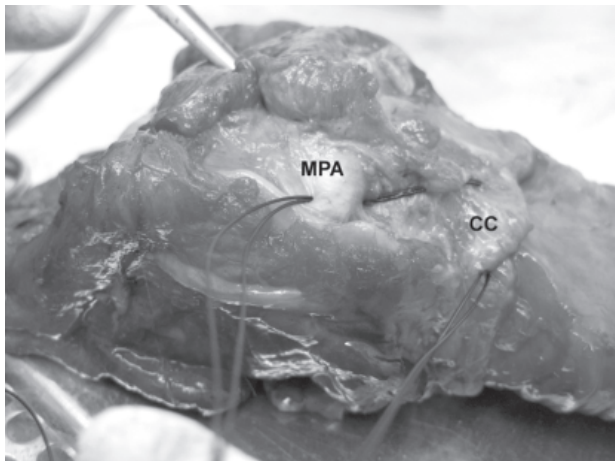
**Fig. 1 Larynx of tiger specimen**

Cutting edge of the thyropharyngeus muscle (TP) of tiger cadaver was transected along the lamina of thyroid cartilage (T)



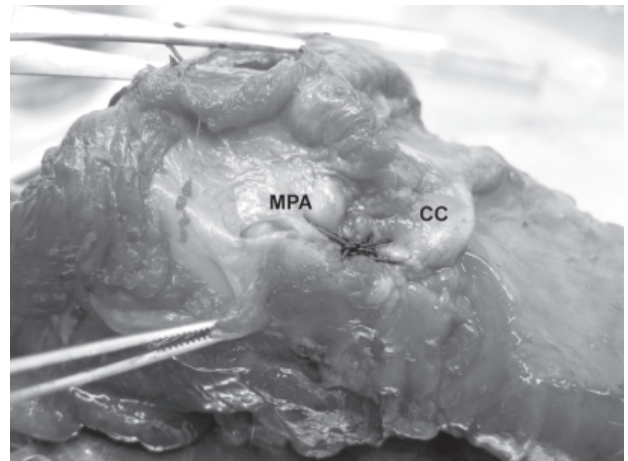
**Fig. 2 Larynx of tiger specimen**

The prosthesis was sutured at caudodorsal aspect of cricoid cartilage (CC), T = thyroid cartilage



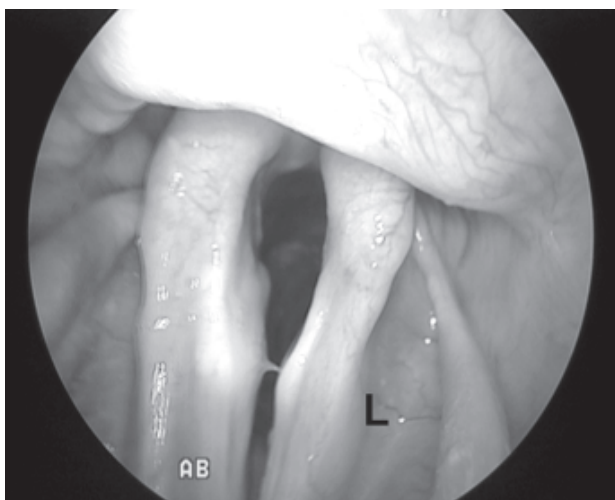
**Fig. 3 Larynx of tiger specimen**

The prosthesis was sutured at muscular process of arytenoid cartilage (MPA)

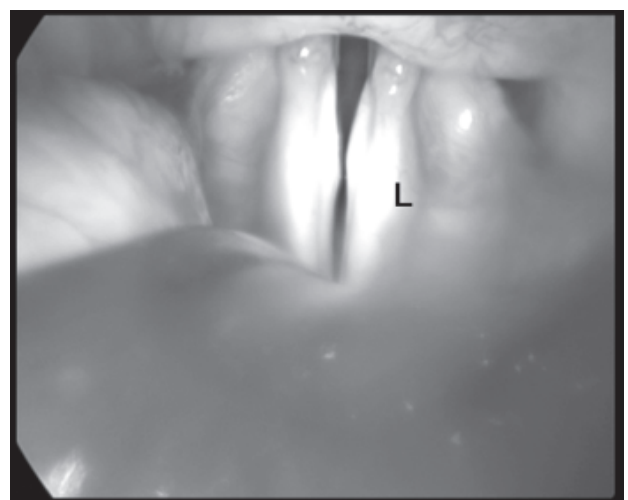


**Fig. 4 Larynx of tiger specimen**

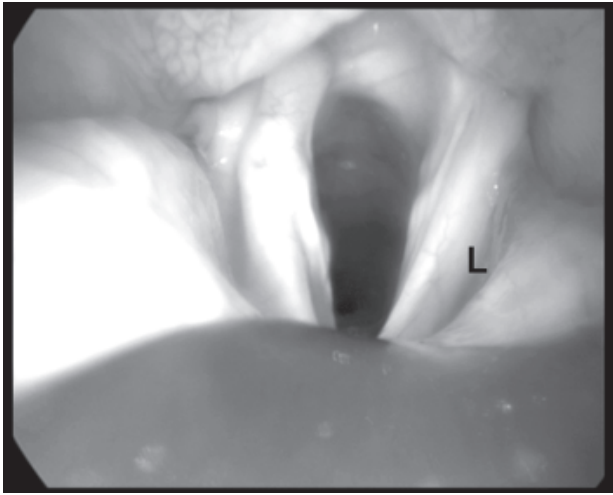
The prosthesis was individually tied



**Fig. 5 Laryngoscopic picture of tiger demonstrated left (L) laryngeal paralysis**



**Fig. 6 Laryngoscopic picture of tiger demonstrated bilateral laryngeal paralysis**



**Fig. 7** Post-operative laryngoscopic picture of tiger in Figure 2 demonstrated increase area of rima glottidis and left arytenoid cartilage (L) was pulled

### Discussion

In the present study, the results suggested arytenoid lateralization is an effective technique for laryngeal paralysis correction in tiger and lion. The unilateral arytenoid lateralization is appropriate for treatment of both unilateral and bilateral laryngeal paralysis. The same as in treatment results of other species such as cat (Hardie et al., 2009; Thunberg and Lantz, 2010), dog (Demetriou and Kirby, 2003; Hammel et al., 2006) and horse (Tetens et al., 1996; Hawkins et al., 1997; Kidd and Slone, 2002). The clinical signs of this abnormality could not be improved by Antibiotics and NSAIDs treatment. However, this may prevent the secondary bacterial infection and relieve of laryngeal mucosal edema. The other technique, permanent tracheostomy has been done in one tiger. The post-operative complications were identified; the tiger had the persistent exudates from the tracheostomy area with coughing. Finally, the aspiration pneumonia was developed from contamination via the tracheostomy wound and the tiger was dead (unpublished data).

The major post-operative complication of the technique presented in this study is aspiration pneumonia as in tiger No. 8. This is the same as other species

(Demetriou and Kirby, 2003; Hammel et al., 2006; Hardie et al., 2009; White, 2009). However, the numbers of the animals in this study are limited, therefore the other complications were not observed.

Regarding the causes of dead, it may be resulting of the improper surgical technique in tiger No.1 which was the first animal treated in this study. The inappropriate of prosthesis in muscular process of arytenoid cartilage was suggested. This may resulting in the laceration of cartilage and the tiger died of apnea. Thereafter, the surgical technique was readjusted and the laceration of the cartilage was not found in the others. The systemic infection was considered as a major cause of dead in lion No. 7. In this case, the concurrent laryngeal paralysis may produce the worse clinical signs. After surgery, the tiger breathed easily with improve clinical signs. Finally, the lion died when the infection had progressed.

The anesthetic risks could be occurred in captive wild felids during induction of anesthesia. Because of the duration of onset could not be predicted when using blow dart anesthetic injection and hypoxia could be easily happened with this ill animal. For this reason, the diagnostic and anesthetic equipments and the emergency drugs should be prepared. Endotracheal intubation could be immediately performed when the animals were anesthetized.

The surgical technique used in wild felids was similar to the technique previously described in cat. This differed from technique used in dog and horse by which the cricothyroid disarticulation and dissection of transverse arytenoids ligament were combined (Hardie et al., 2009). The technique used in this study demonstrated the similar results to the technique used in dog (Griffiths et al., 2001; Demetriou and Kirby, 2003), that made two strands of interrupted suture, first strand is between the dorsolateral cricoid cartilage and muscular process of arytenoid cartilage, the second is between muscular process of arytenoid cartilage and caudodorsolateral

**Table 1.** Summary data of animals with laryngeal paralysis that had arytenoid lateralization

Species	Signalment	Clinical Signs	Duration	Paralysis	Complication	Outcome
Tiger	4 years ,male ,92 Kg.	Inspiratory noise, loss appetite, depress, weight loss	30 days	Bilateral	Recurrent clinical sign 9 days after surgery	Died after surgery 10 days from surgical failure
Tiger	4 years, male, 105 Kg.	Inspiratory noise, loss appetite, depress	10 days	Unilateral-left	None	Still alive 15 months after surgery
Tiger	2 yrs 8mths, male, 100 Kg.	Inspiratory noise, open-mouth breathing, loss appetite, depress	7 days	Unilateral-left	None	Still alive 12 months after surgery
Tiger	2 yrs 6 mths, female, 85 Kg.	Inspiratory noise, wheezes, louder when excited	9 days	Unilateral-left	None	Still alive 8 months after surgery
Tiger	10 years, male, 113 Kg.	Inspiratory noise, louder when excited	20 days	Unilateral-left	None	Still alive 5 months after surgery
Lion	5 years, male, 150 Kg.	Inspiratory noise, wheezes, worse when excited	10 months	Bilateral	None	Still alive 10 months after surgery
Lion	2 years, female, 56 Kg	Inspiratory noise, vomit, anorexia, depress, nasal discharge, weight loss	15 days	Bilateral	Clinical signs not improve and found serosanguinous discharge from surgical wound 7 days after surgery	Died with septicemia 9 days after surgery
Tiger	2 years, male, 110 Kg.	Inspiratory noise, increase inspiratory effort, loss appetite,	7 days	Bilateral	Wound dehiscense 5 days after surgery	Died of aspiration pneumonia 11 days after surgery

surface of thyroid cartilage. Moreover, previous studies in horse used the combined technique ventriculocordectomy with arytenoid lateralization (Tetens et al., 1996; Hawkins et al., 1997; Kidd and Slone, 2002), which demonstrated the similar results with our technique.

For the lateralization sutures, simple interrupted had adequate holding strength for maintain abduction of arytenoid cartilage. Double ligation should be done since the laceration of the suture and muscular process of arytenoid cartilage may occur when single ligation was used. The size of suture material should be related to the size of muscular process of arytenoid cartilage and had adequate strength (polyamide No. 2 is appropriate).

In conclusion, unilateral arytenoid lateralization is suitable surgical technique for unilateral and bilateral laryngeal paralysis correction in wild felids. Bilateral arytenoids lateralization should be performed when the rima glottidis area is not sufficiently increased. Nevertheless, it might has the risk for aspiration pneumonia. In this study, the numbers of animals are limited. Therefore, the further investigation and observation of long-term complications coming from this technique and comparison to other surgical techniques should be done.

### Acknowledgements

We would like to sincerely thank Bueng Chawak Zoo and Kao-Pratapchang Wildlife Breeding Center for providing animals and facilities. We thank Dr.Plern Yongyuttawichai and Dr.Seni Ngamloeporchit for helping in anesthesia and surgery. We also thank Faculty of Veterinary Science, Mahidol University for facility support.

### References

Demetriou J. L. and Kirby B. M. (2003). The effect of two modifications of unilateral arytenoid lateralization on rima glottidis area in dogs. *Vet Surg.* 32 (1): 62-68.

Griffiths L. G., Sullivan M. and Reid S. W. (2001). A comparison of the effects of unilateral thyroarytenoid lateralization versus cricoarytenoid laryngoplasty on the area of the rima glottidis and clinical outcome in dogs with laryngeal paralysis. *Vet Surg.* 30 (4): 359-365.

Hammel S. P., Hottinger H. A. and Novo R. E. (2006). Postoperative results of unilateral arytenoid lateralization for treatment of idiopathic laryngeal paralysis in dogs: 39 cases (1996-2002). *J Am Vet Med Assoc.* 228 (8): 1215-1220.

Hardie R. J., Gunby J. and Bjorling D. E. (2009). Arytenoid lateralization for treatment of laryngeal paralysis in 10 cats. *Vet Surg.* 38 (4): 445-451.

Hawkins J. F., Tulleners E. P., Ross M. W., Evans L. H. and Raker C. W. (1997). Laryngoplasty with or without ventriculectomy for treatment of left laryngeal hemiplegia in 230 racehorses. *Vet Surg.* 26 (6): 484-491.

Kidd J. A. and Slone D. E. (2002). Treatment of laryngeal hemiplegia in horses by prosthetic laryngoplasty, ventriculectomy and vocal cordectomy. *Vet Rec.* 150 (15): 481-484.

Radlinsky M. G., Williams J., Frank P. M. and Cooper T. C. (2009). Comparison of three clinical techniques for the diagnosis of laryngeal paralysis in dogs. *Vet Surg.* 38 (4): 434-438.

Tetens J., Derksen F. J., Stick J. A., Lloyd J. W. and Robinson N. E. (1996). Efficacy of prosthetic laryngoplasty with and without bilateral ventriculocordectomy as treatments for laryngeal hemiplegia in horses. *Am J Vet Res.* 57 (11): 1668-1673.

Thunberg B. and Lantz G. C. (2010). Evaluation of unilateral arytenoid lateralization for the treatment of laryngeal paralysis in 14 cats. *J Am Anim Hosp Assoc.* 46 (6): 418-424.

White R. A. (2009). Canine laryngeal surgery: time to rethink? *Vet Surg.* 38 (4): 432-433.