

Retinal lesion in a *Toxoplasma gondii* seropositive Bengal tiger (*Panthera tigris*) in a private zoo, Kanchanaburi Province

Areerat Kongcharoen¹ Ruangrat Buddhirongawatr^{2,3*} Siriporn Tungsudjai³
Nareerat Sangkhachai³ Poonyapat Sedwisai³ Thekhawet Weluwanarak³
Tatiyanuch Chamsai³

¹Prasu-Arthorn Veterinary Teaching Hospital, Mahidol University Salaya Campus. Phuttamonthon, Nakhonpathom. 73170, Thailand

²Faculty of Veterinary Science, Mahidol University Salaya Campus. Phuttamonthon, Nakhonpathom. 73170, Thailand

³Monitoring and Surveillance Center for Zoonotic Disease in Wildlife and Exotic Animals, Faculty of Veterinary Science, Mahidol University Salaya Campus. Phuttamonthon, Nakhonpathom. 73170, Thailand

*Corresponding author, E-mail address: ruangrat.bud@mahidol.ac.th

Abstract

One of 25 Bengal tigers (*Panthera tigris*) at a private zoo in Kanchanaburi Province had seropositive against *Toxoplasma gondii* infection. The animals were physical and ophthalmic examined during routine annual health check in February, 2013. All of them appeared in normal condition and had no signs of illness. Their blood was tested negative for feline leukemia virus, feline immunodeficiency virus, feline infectious peritonitis virus and *Toxoplasma gondii* using molecular detection of viral antigen. The serological test for *T. gondii* infection was performed by latex agglutination test. The seropositive tiger was a 9 years old female tiger which ophthalmic examination also shown a retinal lesion, a spot of hyperreflective area in right fundus of the right eye. *T. gondii* had been shown to implicate as a major contributor to retinal lesions in felids. Serological evidence and lesion found in the Bengal tiger in this study consistent with *T. gondii* infection. Hence, it was considered as a potential cause. Further study should be performed to confirm the infection and to identify risk factors for prevention.

Keywords: retinal lesion, *Toxoplasma gondii*, Bengal tiger, *Panthera tigris*

รอยโรคที่จอประสาทตาในเสือโคร่งที่ตรวจพบแอนติบอดีต่อการติดเชื้อ *Toxoplasma gondii* ในสวนสัตว์เอกชนในพื้นที่จังหวัดกาญจนบุรี

อารีรัตน์ คงเจริญ¹ รวงรัตน์ พุทธิรงค์วัตร^{2,3*} ศิริพร ตั้งสุดใจ³ นริรัตน์ สังข์ไชย³
บุญญพัฒน์ เศษวิสัย³ ทิมเวท เวฬุวนารักษ์³ ตติยนุช แซ่มใส³

¹โรงพยาบาลสัตว์ประจำสัตว์ คณะสัตวแพทยศาสตร์ มหาวิทยาลัยมหิดล 999 ถ.พุทธมณฑลสาย 4 ต.ศาลายา อ.พุทธมณฑล จ.นครปฐม 73170

²ภาควิชาเวชศาสตร์คลินิกและการสาธารณสุข คณะสัตวแพทยศาสตร์ มหาวิทยาลัยมหิดล

999 ถ.พุทธมณฑลสาย 4 ต.ศาลายา อ.พุทธมณฑล จ.นครปฐม 73170

³ศูนย์เฝ้าระวังและติดตามโรคจากสัตว์ป่า สัตว์ต่างถิ่นและสัตว์อพยพ คณะสัตวแพทยศาสตร์ มหาวิทยาลัยมหิดล

999 ถ.พุทธมณฑลสาย 4 ต.ศาลายา อ.พุทธมณฑล จ.นครปฐม 73170

*ผู้รับผิดชอบบทความ E-mail address: ruangrat.bud@mahidol.ac.th

บทคัดย่อ

จากการตรวจสุขภาพประจำปีของเสือโคร่งจำนวน 25 ตัว ที่สวนสัตว์เอกชนแห่งหนึ่งในเดือนกุมภาพันธ์ 2556 พบเสือ 1 ตัว อายุ 9 ปี ให้ผลบวกต่อเชื้อ *T.gondii* ด้วยการตรวจวิธี Latex agglutination และพบรอยโรคลักษณะเป็นบริเวณที่มีการ สะท้อนแสงมากผิดปกติบนจอประสาทตาของตาด้านขวา ผลการตรวจอื่นๆ ได้แก่ FeLV, FIV, FIP และ *T.gondii* ด้วยวิธี PCR ให้ผลลบ ผลการตรวจสุขภาพทั่วไปไม่พบความผิดปกติและเสือไม่มีอาการป่วย ทั้งนี้ *T.gondii* เป็นเชื้อโรคที่ทำให้เกิดรอยโรค ที่จอประสาทตาได้โดยเฉพาะในสัตว์ตระกูลแมว จากกรณีศึกษานี้พบว่าเสือมีรอยโรคที่จอประสาทตาและมีผลบวกต่อการตรวจ *T.gondii* ดังนั้น รอยโรคอาจเกี่ยวข้องกับการติดเชื้อชนิดนี้ แต่ควรมีการศึกษาเพิ่มเติมเพื่อยืนยันการติดเชื้อและหาปัจจัยเสี่ยง เพื่อประโยชน์ในการป้องกันโรคต่อไป

คำสำคัญ : รอยโรคที่จอประสาทตา ที่อกโซพลาสมา กอนได เสือโคร่ง

Introduction

Retinal lesions in domestics and wild felids are usually secondary to disease processes. The lesions extend from choroid resulting in inflammation or degeneration of retina. There are various causes of retinal lesions including hereditary diseases, nutritional deficiencies, trauma of the head region, hypertension, and several infectious diseases such as feline infectious peritonitis (FIP), feline leukemia virus infection (FeLV), cryptosporidiosis, and toxoplasmosis (Gelatt, 2004; Ofri et al. 1996). Toxoplasmosis caused by *Toxoplasma gondii*, the common parasitic zoonosis widely reported (Dubey and Beatties ,1988). Cat and other feline species are definitive host for this organism and *T.gondii* has been implicated as a major contributor to feline uveitis and chorioretinitis is the most common ocular manifestation (Pfaff et al., 2014; Holland, 1999; Kijlstra and Petersen, 2014; Garweg and, Stanford, 2013;. Rodriguez et al., 1996; Pleyer et al. 2007).

In Thailand, the incidence of *T. gondii* infection in humans was 2.3-21.9% but in some European countries the incidence was up to 90-93% (Sukthana,2006). Seroprevalence study of toxoplasmosis in domestic cats in Thailand reported the seropositive 4.8-10.1% (Sukthana et al, 2003, Jittapalpong et al, 2007, 2010, Sukhumavasi et al, 2012). The seroprevalences in healthy captive wild felids were about 15.4- 42.8% (Thiangtam et al, 2006) (Buddhirongawatr et al, 2006). A study in Brazil reported 64.9% of wild felids from 12 zoos were *T. gondii* seropositive (Silva et al, 2002). Another study in the United State reported the *T. gondii* seropositive of 22.4% in free range puma (*Felis concolor*) and 51.7% in free bobcat (*Lynx rufus*) (Kikhuchi et al, 2004).

Data from seroprevalence studies indicated that toxoplasmosis is common in feline populations. However, the clinical findings in those populations both in captive and free range in nature are still limited. Thiangtum et al., 2006 reported infected tigers showed clinical signs of convulsion, dropped head roaring and

die and pathological findings include cardiomyositis, hepatitis and encephalitis. Lloyd and Stidworthy (2007) have reported *T. gondii* infection in a juvenile cheetah (*Actinonyx jubatus*). The animal showed signs of rapidly progressive pyrexia, tachypnea, abdominal effusion, and hepatomegaly. Postmortem examination revealed *T. gondii* in multiple organs. This study examined physically normal Bengal tigers and described clinical findings found in the tiger which had seropositive against *T. gondii* infection.

Case:

All of 25 Bengal tiger (*Panthera tigris*) from a private zoo in Kanchanaburi Province were subjected for annual health examination in February, 2013. They were given general anesthesia using standard protocol (Fowler and Eric, 2003). Medication used for general anesthesia were atropine sulphate 0.01mg/kg as a premedication followed by xylazine hydrochloride 1 mg/kg and ketamine hydrochloride 4 mg/kg intramuscularly. Blood was collected from median saphenous vein for 10 ml., divided into aliquoted to 3 ml. in EDTA tube and 7 ml. Tube. Laboratory test were performed at Faculty of Veterinary Science, Mahidol University.

Whole blood in EDTA was subjected for various tests; and analysis for haematological profile, examination for blood parasite, and antigens identification for feline immunodeficiency virus (FIV), FeLV, FIP, and *T.gondii* by PCR technique. The primer used for molecular detection of antigens are as follows (Matteucci et al., 1993): **Feline Infectious Peritonitis virus (FIP) gene FIV gag 346 bp:** FIPV1-M-26517F 5'ATg CAT ACT CTg AgT ACC AAg TTT CCA g 3'#, FIPV1-M-26863R 5'AAC gAT ggT TCT ACT Agg TgT AgC AAT CAT g 3'#, **Toxoplasma gondii SAG1 gene, primer Toxo 914 bp:** Toxo_SAG1_DS29 5'TTg CCg CgC CCA CAC TgA Tg 3'#, Toxo_SAG1_DS30 5'CgC gAC ACA AgC TgC gAT Ag 3'#, **Feline Leukemia Virus (FeLV): GAG out 350 bp:** FeLV-gag 98F 5'Cgg gCg CgC

AAg TcTTTg CTg AgAC 3', FeLV-gag 440R 5'CAg ACA CCC gTg gAA CgT CTT CCA gg 3', **GAG in 147 bp:** FeLV-gag 164F 5'gCA TCT gAC TCg Tgg TCT Cg 3', FeLV-gag 310R 5'CCA gCT TAC CTC CTg ATG gTg 3', **LTR 150 bp** FeLV-LTR-out-F2 5iAgg AKA TCT gTg gTT AAg CAC CTg ggC C 3'FeLV-LTR-out-R2 5'ggg AgC CTg gAg ACT gCT ggC Ag 3', **Feline immunodeficiency virus (FIV): FIV gag 197 bp:** FIV-gag-666F 5'ggC CAT TAA gAg ATg TAg TA 3', FIV-gag-863R 5'ATT gCC ATA TCA ATT TCC TT 3'.

Serum was analysed for biochemical profiles and indirect latex agglutination test (ILAT) was performed to examine for *T.gondii* antibody titer.

Radiographic and ultrasonography of the thorax and abdomen were performed. The dental check and scaling were included as a routine health examination. Ophthalmologic examination was performed with focal light source, a Shirmer's Tear Test strips (Schering Plough Animal Health Corporation, Intervet, Thailand). The intraocular pressure was measured by applanation tonometer (TonoPen XL, Medtronic, USA). Fundus was examined by Pan-Optic (Welch Allyn, USA) and photographed by fundus camera (Kowa Genesis-D Retinal Camera; Kowa, Japan).

Results

In the *T.gondii* seropositive tiger, all of parameters from haematological examination were in normal range (Table 1.) No blood parasite was detected. Antigen detection for FIV, FeLV, FIP, and *T.gondii* using PCR technique were negative. Serum biochemistry profile was in normal range (Table 2.). Antibody titer against *T.gondii* presented at 1:64 level while the cut off value to determine for toxoplasmosis was $\geq 1:64$.

Radiographic and ultrasonography of the thorax and the abdomen were unremarkable for organs abnormalities. The ophthalmologic findings were clear ocular media, STT were 27 and 28 mm/min, IOP were 23 and 25 mmHg in the left and right eye respectively. The funduscopy of the left eye was normal. A focal

hyperreflective area of the tapetal fundus was found in the right eye. (Figure 1).

Conclusion and Discussion

We examined 25 Bengal tigers in a zoo during a routine annual health check. The only abnormality found was retinal lesion in one tiger which had seropositive for *T.gondii*. It was an inactive inflammatory lesion located in the tapetal fundus and was seen as hyperreflective area with sharp edges. This could be a result from previous pathological processes such as chorioretinitis, focal exudative retinal detachment. These conditions, especially in feline, are systemic problems. Some infectious diseases causing retinal lesion besides toxoplasmosis also included FIV, FeLV, and FIP but these were ruled out because PCR tests failed to detect the viruses and haematological profiles which were in normal range did not correlate with those infections.

Here in *T. gondii* infection was considered as the potential cause of the retinal lesion in the Bengal tiger. Ocular toxoplasmosis had been demonstrated in previous experimental infection study in which the infected cats had only retinal lesions with or without signs of other abnormalities (Dubey and Carpenter, 1993). In our study the presence of antibody against *T. gondii* in the tiger together with an absence of the parasite DNA in blood as well as the characteristic of retinal lesion suggested past infection. For diagnosis of active infection, histologic demonstration of the parasite or alternatively identification of parasite DNA is the definitive means to confirm toxoplasmosis (Gelatt, 2004).

The prevalence of seropositive animals in this study was 4% compared with 15.4- 42.8% from surveys in healthy captive felids by Thiangtam et al. (2006) and Buddhirongawatr et al. (2006). Toxoplasmosis can fatally affect animals and humans, therefore, the preventive measures to prevent toxoplasmosis and annual health check should be carried on in zoo animals.

Table 1. A result of complete blood count, blood chemistry profile of the tiger compare with reference values.

parameter	unit	value	Reference values*
WBC	$\times 10^3/\mu\text{l}$	6.0	4-24
RBC	$\times 10^6/\mu\text{l}$	7.38	4.56-10.7
Hb	g/dl	14.1	8.4-22.0
Hct	%	41	25-67
MCV	fl	57	38.8-93.1
MCH	pg/cell	19.2	12.1-29.9
MCHC	g/dl	33.6	17.5-46.5
Platelet	$\times 10^3/\mu\text{l}$	238	65-525
Segmented neutrophil	$\times 10^3/\mu\text{l}$	74	35-75
Band neutrophil	$\times 10^3/\mu\text{l}$	0	0-4
Lymphocyte	$\times 10^3/\mu\text{l}$	20	20-35
Monocyte	$\times 10^3/\mu\text{l}$	1	0-4
Eosinophil	$\times 10^3/\mu\text{l}$	5	2-12
Basophil	$\times 10^3/\mu\text{l}$	0	rare

*"International Species Information System". *isis.org*. International Species Information System. 2008

Table 2. Blood chemistry profile value

parameter	unit	value	Reference values*
Blood urea nitrogen	mg/dl	32	14-56
Creatinine	mg/dl	3.8	1.8-3.6
Creatine kinase	IU/l	213	25-2500
Alkaline phosphatase	IU/l	11	5-124
Alanine aminotransferase	IU/l	32	22-371
Aspartate aminotransferase	IU/l	29	6-148
Total protein	g/dl	8.0	0-423
Albumin	g/dl	3.8	2.7-5.5

*"International Species Information System". *isis.org*. International Species Information System. 2008

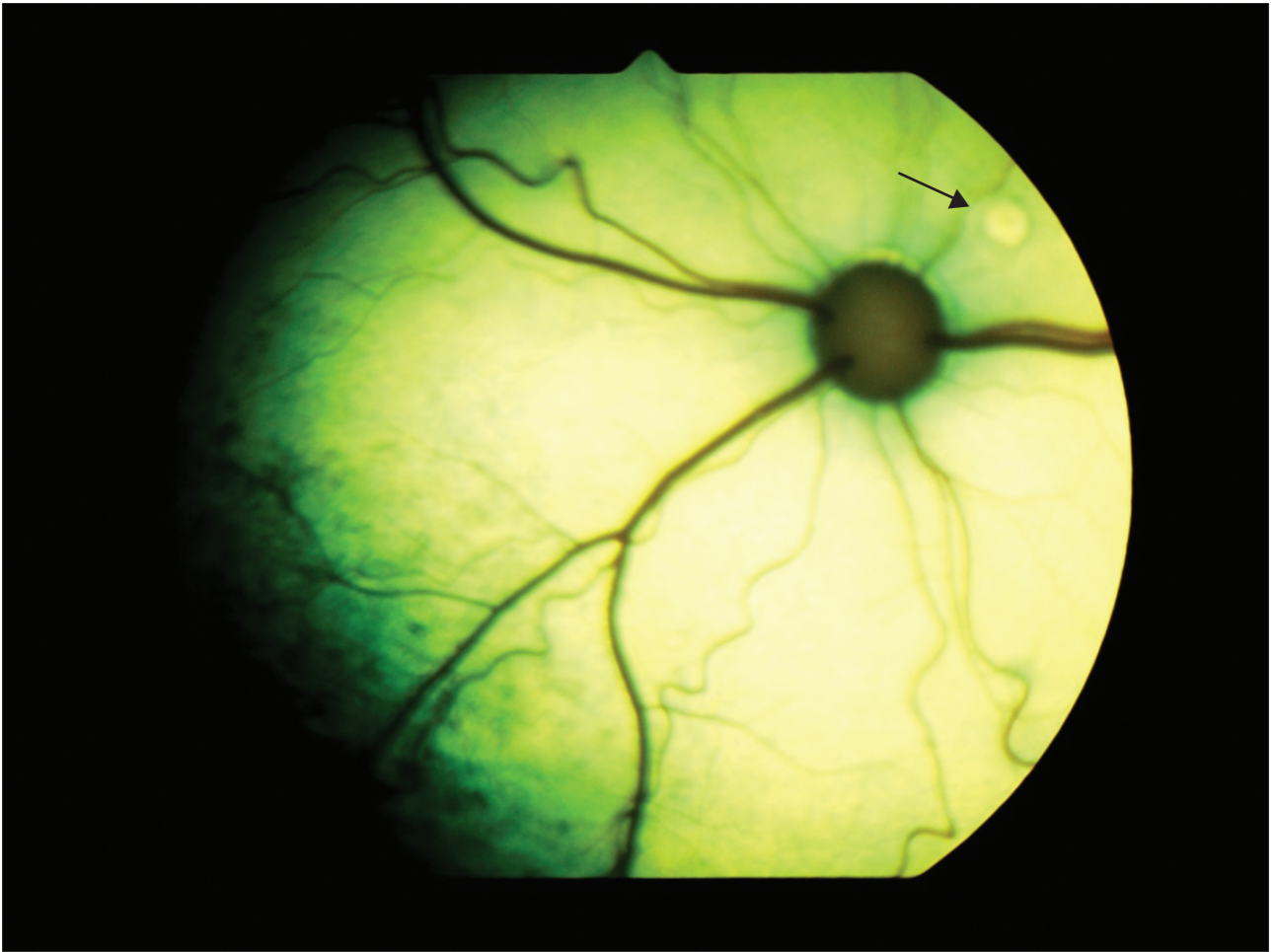


Figure 1 A round hyperreflective retinal lesion in the right eye in a 6 years old female Bengal tiger (*Panthera tigris*) (arrow).(Kowa Genesis-D Retinal Camera; Kowa, Japan)

References

- Buddhirongawatr R, Tungsudjai S, Chaichoune K, Sangloun C, Tantawiwattananont, Phonakguen R, Sukthana Y. (2006): Detection of *Toxoplasma gondii* in captive wild felids. *Southeast Asian J Trop Med Public Health* 37; 15-17.
- Dubey JP and Beattie CP. (1988). Toxoplasmosis of animals and man. CRC Press Inc., Boca. P.
- Dubey JP and Carpenter JL. (1993). Histologically confirmed clinical toxoplasmosis in cats: 100 cases (1952-1990). *J Am Vet Med Assoc.* 203(11): 1556-66
- Fowler ME and Miller RE. (2003). Zoo and Wild Animal Medicine 5th Edition. Missouri: Elsevier Science, 491-501
- Garweg JG and Stanford MR, (2013). Therapy for ocular toxoplasmosis—the future. *Ocul Immunol Inflamm.* 2013 Aug; 21(4): 300-5.
- Gelatt KN. (1999). Veterinary Ophthalmology. 3rd Edition. Lippincott Williams and Wilkin, 1672p.
- Holland GN. (1999). Reconsidering the Pathogenesis of Ocular Toxoplasmosis. *Am J n Ophthalmol.* 128; 502-505.
- Jittapalapong S, Inpankaew T, Pinyopanuwat N, Chimnoi W, Kengradomkij C, Wongnarkpet S, Maruyama S, Lekkla A, Sukthana Y. (2010). Epidemiology of *Toxoplasma gondii* infection of stray cats in Bangkok, Thailand. *Southeast Asian J Trp Med Public Health.* 41(1): 13-8.
- Jittapalapong S, Nimsupan B, Pinyopanuwat N, Chimnoi W, Kabeya H, Maruyama S. (2007). Seroprevalence of *Toxoplasma gondii* antibodies in stray cats and dogs in the Bangkok metropolitan area, Thailand. *Vet Parasitol.* 145(1-2): 138-41.
- Kijlstra A , and Petersen E. (2013). Epidemiology, pathophysiology, and the future of ocular toxoplasmosis. *Ocul Immunol Inflamm.* 2014 Apr; 22(2): 138-47.
- Kikuchi Y, Chomel BB, Kasten RW, Materson JS, Swift PK, O'Brien SJ. (2004). Seroprevalence of *Toxoplasma gondii* in American free-ranging or captive pumas (*Felis concolor*) and bobcats (*Lynx rufus*). *Vet Parasitol.* 120; 1-9.
- Little L, Shokek A, Dubey JP, Deheer HL. (2005). *Toxoplasma gondii*-like organisms in skin aspirates from a cat with disseminated protozoal infection. *Vet Clin Pathol* 34; 156-60.
- Lloyd C, Stidworthy F. (2007). Acute disseminated toxoplasmosis in a juvenile cheetah (*Acinonyx jubatus*). *J Zoo Wildl Med.* 38; 475-8.
- Matteucci D, Baldinotti F, Mazzetti P, Pistello M, Bandecchi P, Ghilarducci R, Poli A, Tozzini F, and Bendinelli M. (1993). Detection of feline immunodeficiency virus in saliva and plasma by cultivation and polymerase chain reaction. *J Clin Microbiol.* 31(3): 494-501.
- Silva CR, Ogasawara S, Maryulo MF, Ferreina-Neto JS, Dubey JP. (2002). *Toxoplasma gondii* antibodies in exotic wild felids from Brazilian zoos. *J Zoo Wildl Med.* 32; 349-51.
- Ofri R, Barishak RY, Esahkar G and Aizenberg I. (1996). Feline Central Retinal Degeneration in Captive Cheetahs (*Acinonyx jubatus*). *Journal of Zoo and Wildlife Medicine.* 27; 101-108.
- Pfaff AW, de-la-Torre A, Rochet E, Brunet J, Sabou M, Sauer A, Bourcier T, Gomez-Marin JE, Candolfi E. (2014). New clinical and experimental insights into Old World and neotropical ocular toxoplasmosis. *Int J Parasitol.* 44(2): 99-107.
- Pleyer U, Torun N, Liesenfeld O. (2007). Ocular Toxoplasmosis. *Ophthalmologe.* 104; 603-616.
- Rodriguez A, Calonge M, Pedroza-Seres M, Akova YA, Messmer EM, D'Amico DJ, Foster CS. 1996. Referral Patterns of Uveitis in a Tertiary Eye Care Center. *Arch Ophthalmol.* 114(5): 593-599.

- Sukhumavasi W, Bellosa ML, Lucio-Forster A, Liotta JL, Lee AC, Pornmingmas P, Chungpivat S, Mohammed HO, Lorentzen L, Dubey JP, Bowman DD. (2012). Serological survey of *Toxoplasma gondii*, *Dirofilaria immitis*, Feline Immunodeficiency Virus (FIV) and Feline Leukemia Virus (FeLV) infections in pet cats in Bangkok and vicinities, Thailand. *Vet Parasitol*. 13; 188(1-2): 25-30.
- Sukthana Y, Kaekangwal J, Jantanavivat C, Lekkla A, Chiabchalard R, Aumarm W. (2003). *Toxoplasma gondii* antibody in Thai cats and their owners. *Southeast Asian J Trp Med Public Health*. 34; 733-8.
- Sukthana Y. (2006). Toxoplasmosis: beyond animals to humans. *Trends in Parasitol* 22; 137-142.
- Thiangthum K, Nimsuphan B, Pinyopanuwat N, Chimnoi W, Tunwatta W, Tongthainan D, Jittapalapong S, Rukkwamsuk T, Maruyama S. (2006). Seroprevalence of *Toxoplasma gondii* in captive felids in Thailand. *Vet Parasitol* 136; 351-355.