

Case Report: Bronchoesophageal Fistula in Mixed Breed Dog

Phingphol Charoonrut¹ Nattapon Riengvirodkij² Chanon Kamta^{2*}

¹Department of Clinical Sciences and Public Health, Faculty of Veterinary Science, Mahidol University,
Phuttamonthon 4 Rd, Nakhon Pathom 73170, Thailand

²Prasu-arthorn Animal Hospital, Faculty of Veterinary Science, Mahidol University,
Phuttamonthon 4 Rd, Nakhon Pathom 73170, Thailand

*Corresponding author, E-mail address: chanon_helix@hotmail.com

Abstract

A 10-year-old, male neutered, 10 kg, mixed poodle was presented with a 4-month history of non-productive cough. The dog was firstly diagnosed pneumonia at the left caudal lung lobe. However, the treatment with systemic antibiotics, mucolytics and bronchodilators did not improve his clinical signs. Moreover, the regurgitation with foamy content was developed. The esophagoscopy and contrast radiography with barium sulfate solution were performed for the definite diagnosis. The bronchoesophageal fistula with secondary pneumonia at the left caudal lung lobe was diagnosed. The specific treatment for the bronchoesophageal fistula was performed by the surgical correction via thoracotomy.

Keywords: Bronchoesophageal fistula, chronic cough, regurgitation

รายงานสัตว์ป่วย : ภาวะรูทีระหว่างหลอดลมและหลอดอาหาร ในสุนัขพันธุ์ผสม

พิงพล จรุงรัตน์¹ ณัฐพล เรียงวิโรจน์กิจ² ชานนท์ จำตา^{2*}

¹ภาควิชาเวชศาสตร์คลินิกและการสาธารณสุข คณะสัตวแพทยศาสตร์ มหาวิทยาลัยมหิดล พุทธมณฑลสาย 4 ศาลายา นครปฐม 73170

²โรงพยาบาลสัตว์ประจวบคีรีขันธ์ คณะสัตวแพทยศาสตร์ มหาวิทยาลัยมหิดล พุทธมณฑลสาย 4 ศาลายา นครปฐม 73170

*ผู้รับผิดชอบบทความ E-mail address: chanon_helix@hotmail.com

บทคัดย่อ

สุนัขพันธุ์พุดเดิ้ลผสม เพศผู้ ทำหมันแล้ว อายุ 10 ปี อาการไอแบบไม่มีเสมหะมานานประมาณ 4 เดือน ได้รับการวินิจฉัยเบื้องต้นจากคลินิกว่าป่วยด้วยโรคปอดอักเสบที่บริเวณกลีบปอดหลังด้านซ้าย แต่สุนัขไม่ตอบสนองต่อการรักษาด้วยการให้ยาปฏิชีวนะ ยาละลายเสมหะ และ ยาขยายหลอดลม ต่อมาภายหลังพบว่าสุนัขมีอาการขย้อนลักษณะเป็นฟองขาวจึงทำการวินิจฉัยซ้ำด้วยการส่องกล้องหลอดอาหาร และเอ็กซเรย์ร่วมกับการใช้สารทึบแสงประเภทแบเรียม ซัลเฟต พบว่าสุนัขป่วยด้วยภาวะรูทีระหว่างหลอดลมและหลอดอาหารร่วมกับปอดอักเสบที่บริเวณกลีบปอดหลังด้านซ้าย จึงทำการรักษาโดยการเปิดผ่าช่องอกเพื่อทำการแก้ไขความผิดปกติที่พบ

คำสำคัญ : รูทีระหว่างหลอดลมและหลอดอาหาร ไอเรื้อรัง การขย้อน

Signalment and history:

A 10-year-old, male neutered, 10 kg, mixed poodle presented with a 4-month history of non-productive cough. The dog had been treated at a referring practice but the clinical signs had still remained. He has completed vaccination and heartworm prevention program.

Physical Examination:

The dog was bright, alert and responsive during physical examination. The body condition score was 3/5. A systolic heart murmur, grade III/VI was detected at mitral area. The heart rate was 140 beats/minute with regular pulse and no evidence of pulse deficit. The respiratory rate was 30 breaths/minute. The lung sounds were normal at both cranial lung lobes, but the crackle lung sound and increased bronchovesicular sound were auscultated from the left caudal and right caudal lung lobes. The body temperature was 102.5 °F. The other findings from physical examination were unremarkable.

Problem list:

The specific problems in this dog were chronic non-productive cough, and grade III/VI systolic murmur at mitral area.

Differential diagnosis:

The chronic non-productive cough may be a result of chronic respiratory diseases or cardiovascular diseases. The differential diagnosis of chronic respiratory diseases was tracheal collapse, tracheal stenosis, tracheal foreign body, parasites, chronic bronchitis and chronic respiratory tract infection. The cardiovascular diseases may include the left atrial enlargement (mitral regurgitation and dilated cardiomyopathy), and heartworm disease.

Case management and follow up:

Thoracic radiography, hematology and serum biochemistry profiles were performed to identify the

primary cause of the problems and to evaluate the overall patient health status.

The hematology and serum biochemistry profiles were normal, except the high number of platelet counts (Table 1). Thrombocytosis could be caused by an abnormal platelets production from the bone marrow, but it could also be caused by normal variation in aging dog. This finding was not considered for seriously investigation because it was not related to the clinical signs of the dog.

The alveolar lung pattern at the left caudal lung lobe and the unstructured interstitial lung pattern at the right caudal lung lobe were revealed from the thoracic radiography (Figure 1). The vertebral heart score was 9.5 (normal 8.7 - 10.7) (Buchanan and Bucheler, 1995). The differential diagnosis was chronic respiratory infection (pneumonia or bronchopneumonia) and chronic bronchitis. Then, enrofloxacin at the dose of 5 mg/kg (Hawkins et al., 1998) once daily and carbocysteine at the dose of 200 mg/day were prescribed.

One week later, the dog still presented with non-productive cough. The positive tracheal pinch was noted during physical examination. Therefore, aminophylline at the dose of 10 mg/kg twice a day and prednisolone at the dose of 1 mg/kg/day were prescribed to control the inflammation of the bronchi. The owner was suggested to control the body weight of the dog.

The clinical sign was improved within 1 week after the new treatments, although an abnormal bronchovesicular sound was still detected from the thoracic auscultation. The thoracic radiography showed an unstructural interstitial pattern at both left and right caudal lung lobes. Moreover, leukocytosis was revealed from hematology (Table 1), enrofloxacin at the dose of 5 mg/kg was later prescribed instead of corticosteroids to control infection.

A week later, the dog was presented at the hospital because of severe non-productive cough, tachycardia, tachypnea, and fever (103.8 °F). The dog

still had a leukocytosis, but the total white blood cell count was decreased, comparing to the previous test (Table 1). Furthermore, the echocardiography was performed to rule out the cause of infection at the valve leaflets.

Chronic valvular degeneration (CVD), class B1, was diagnosed from the echocardiography. Then, the dog was continued to treat the respiratory tract infection and chronic bronchitis with amoxicillin-clavulanic acid at the dose of 12.5 mg/kg twice a day, mucolytics, bronchodilators, corticosteroids and nebulization with normal saline solution plus gentamicin.

During corticosteroids administration, severe non-productive cough was markedly reduced, whereas vomiting with foamy content was developed. Therefore, metoclopramide at the dose of 0.4 mg/kg, ranitidine at the dose of 1.5 mg/kg and sucralfate at the dose of 125 mg/dog were prescribed for symptomatic treatment. In addition, the owner reported that vomiting occurred immediately after drinking. Thoracic radiography was then carried out to identify the cause of regurgitation.

The fluoroscopy was performed to evaluate the motility of the esophagus. The esophagoscopy was also planned to investigate the cause of hypomotility of the esophagus. The owner was trained to feed the dog in the upright position for reducing regurgitation.

The esophagoscopy revealed normal appearance of the esophageal wall, but an esophageal fistula, diameter of 0.5 cm width, was detected (Figure 2). Mucopurulent exudate was found at the ending area of the fistula tract. Further contrast study with 30% w/v barium meal under the fluoroscopy was performed to confirm the abnormal connection between the esophagus and the chest cavity. Barium was diffused from the esophagus to the primary bronchi of the left caudal lung lobe and partial area of the right caudal lung lobe (Figure 3). Therefore, the definitive diagnosis of this dog was bronchoesophageal fistula with secondary pneumonia caused by aspiration of water and food through the fistula. The specific treatment for

the bronchoesophageal fistula is surgical correction. The dog was fed by nasogastric tube and continued enrofloxacin until the operation.

The dog was premedicated with diazepam at a dose of 0.5 mg/kg and induction with propofol at a dose of 3 mg/kg intravenously. Enrofloxacin at the dose of 5 mg/kg and tramadol hydrochloride at a dose of 4 mg/kg were subcutaneously injected before the operation. Isoflurane was used as a maintenance general anesthesia in this dog.

The thoracotomy was performed at the left chest wall in the right lateral recumbency position (Figure 4). The endotracheal tube was placed for connect to the mechanical ventilator. The esophagoscopy was used for indentify the lesion in the esophageal cavity. Unfortunately, the dog died during the operation.

Discussion

The bronchoesophageal fistula is a rare abnormal connection between the esophagus and bronchus/bronchi. This phenomenon was found in dogs and cats (Nawrocki et al., 2003). In dogs, this abnormality could be congenital or acquired disease. The abnormal separation of the respiratory tract and esophagus during embryonic development is the major cause of this disease in humans (Della Ripa et al., 2010). The acquired bronchoesophageal fistula was caused by several factors, for example; esophageal foreign bodies, chronic inflammation, neoplasia and abscess in the respiratory tract (Nawrocki et al., 2003). In this case, we did not find any specific lesion of the causes, but esophageal foreign bodies or chronic inflammation is the most possible. The breeds that commonly affected by this abnormality in dogs are miniature poodles, Cairn terrier and others small breed dogs (Della Ripa et al., 2010).

Chronic coughing, dyspnoea, anorexia, depression, weight loss, regurgitation, dysphagia and crackles lung sound are commonly presented during physical examination (Della Ripa et al., 2010). Complete blood

count revealed neutrophilia (Basher et al., 1991) and a transtracheal wash demonstrated a suppurative inflammatory response with *Escherichia coli*, *Staphylococcus intermedius*, *Bacteroides fragilis* and *Actinomyces spp.* (van Ee et al., 1986).

A plain thoracic radiograph may reveal an alveolar lung pattern, pleural effusion, pulmonary consolidation, interstitial lung pattern, bronchial lung pattern, esophageal foreign bodies or esophageal dilatation (Della Ripa et al., 2010). One report showed that the esophageal fistula commonly connected between the caudal oesophagus to the pleural space, caudal or middle right lung lobes (Fox et al., 1995). On the contrary, we reported in the present study that the lesion was found at the left caudal lung lobe, which may not be commonly affected.

Endoscopy, contrast esophagoscopy and histopathology are usually required for the final diagnosis of the bronchoesophageal fistula (Della Ripa et al., 2010). A contrast study using a 20 - 30% w/v barium sulfate solution should be performed to locate the abnormal connection between the esophagus and the respiratory tract (Basher et al., 1991). Lung injury is not expected to occur by barium sulfate because of its non-irritant nature. However, inflammation of the lungs or death due to high or low density of barium sulfate have been found in human (Fruchter and Dragu, 2003). Using the iodinated contrast solution may result in pulmonary edema due to its hyperosmolarity effect and should be avoided in this case (Della Ripa et al., 2010).

Esophagoscopy may be performed during general anesthesia to identify the fistula and other lesions in the esophagus. Moreover, bronchoscopy and bronchoalveolar lavage should be attempted to visualize the problem in the respiratory tract and collection sample for cytology and culture (Della Ripa et al., 2010).

Surgical correction was considered the treatment of choice for bronchoesophageal fistula (Basher et al., 1991). The anesthesia may difficult and high risk due to

abnormal connection between the esophagus and bronchi, resulting in the gastric content flooding in the tracheobronchial tree (Della Ripa et al., 2010). Preoperative gastrotomy or endobronchial intubation was employed to prevent this complication in humans (Parker and Caywood, 1987). In the present case, the fistula was located between the esophagus and left caudal lobar bronchus. Thus, the intubation of the right main stem bronchus should be performed to avoid the ventilatory problems and loss of anesthetic gases during surgical correction of the fistula.

It has been reported that the success rate of surgical correction for the bronchoesophageal fistula was low (Basher et al., 1991). The prognosis depended on the preoperative status of the patients. A good prognosis was only associated with a few complications before and after surgical management (Della Ripa et al., 2010).

In conclusion, the bronchoesophageal fistula is a rare disease, which is very difficult to diagnose and manage. The patient that is presented with chronic coughing, chronic respiratory tract infection and regurgitation should be concerned for this abnormality. The definite diagnosis could be done by contrast radiography and esophagoscopy. Surgical correction is the treatment of choice. The prognosis is ranging from good to guarded.

Table 1: The hematology and serum biochemistry profiles.

Test	Sep 10, 2013 Result	Sep 23, 2013 Result	Oct 10, 2013 Result	Reference
WBC (cell/mm ³)	14,900	27,600	19,400	6,000 - 17,000
Neutrophil	13,112	26,496	16,102	3,000 - 11,500
Band	0	0	1,940	0 - 300
Monocyte	0	828	970	150 - 1,350
Lymphocyte	1,490	276	194	1,000 - 4,800
Eosinophil	298	0	194	100 - 1,250
Basophil	0	0	0	< 100
RBC x 10 ⁶ (cell/mm ³)	6.46	-	-	5 - 9
Hb (g/dL)	13.4	-	-	10 - 18
Hct (%)	39.5	-	-	35 - 55
MCV (fL)	61.2	-	-	60 - 77
MCH (pg)	20.8	-	-	20 - 25
MCHC (g/dL)	33.9	-	-	32 - 36
Plt x 10 ³ (cell/ul)	785	-	-	200 - 500
Plasma protein (g/dL)	10	-	-	6 - 7.5
Blood parasite	Not found	-	-	Not found
ALT (U/L)	53	-	-	10 - 100
ALP (U/L)	14	-	-	23 - 212
Blood Urea Nitrogen (BUN) (mg/dL)	12	-	-	7 - 27
Creatinine (mg/dL)	0.8	-	-	0.5 - 1.8

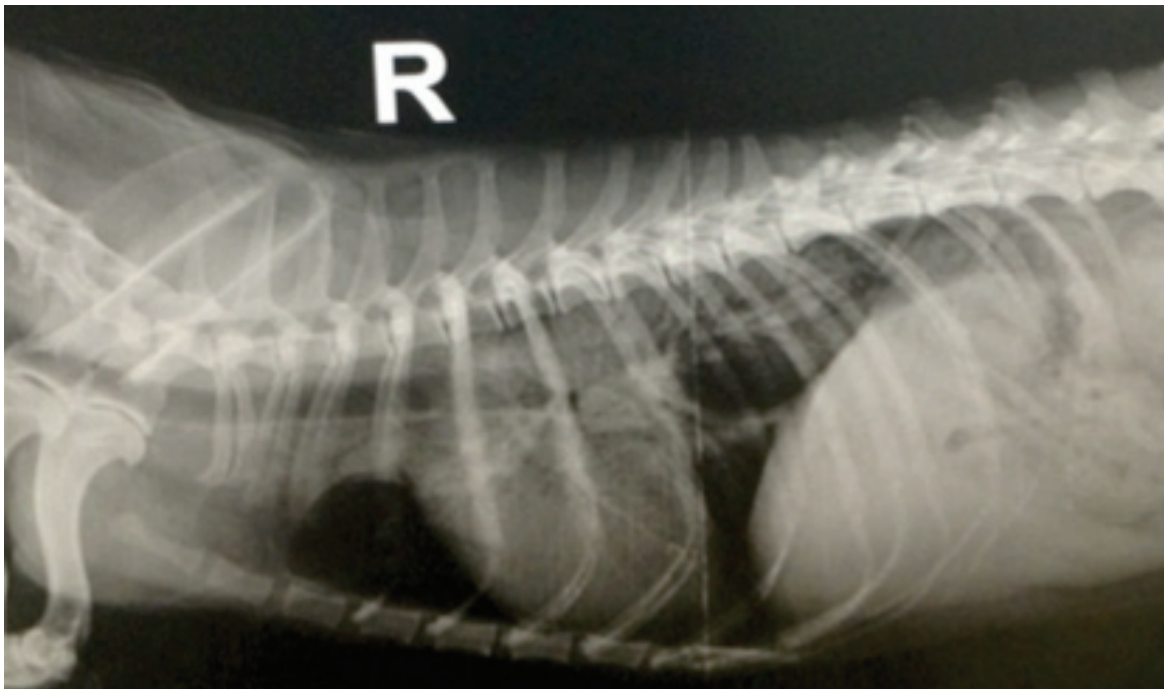


Figure 1a: The alveolar lung pattern at the caudal lung lobe in lateral position.

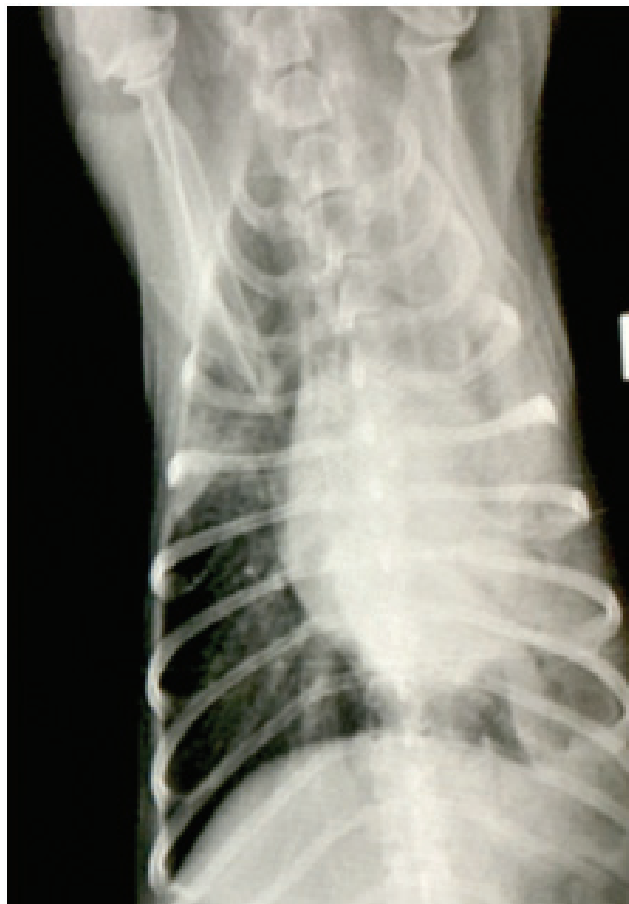

Figure 1b: The alveolar lung pattern at the left caudal lung lobe and the unstructured interstitial lung pattern at the right caudal lung lobe in ventrodorsal position.

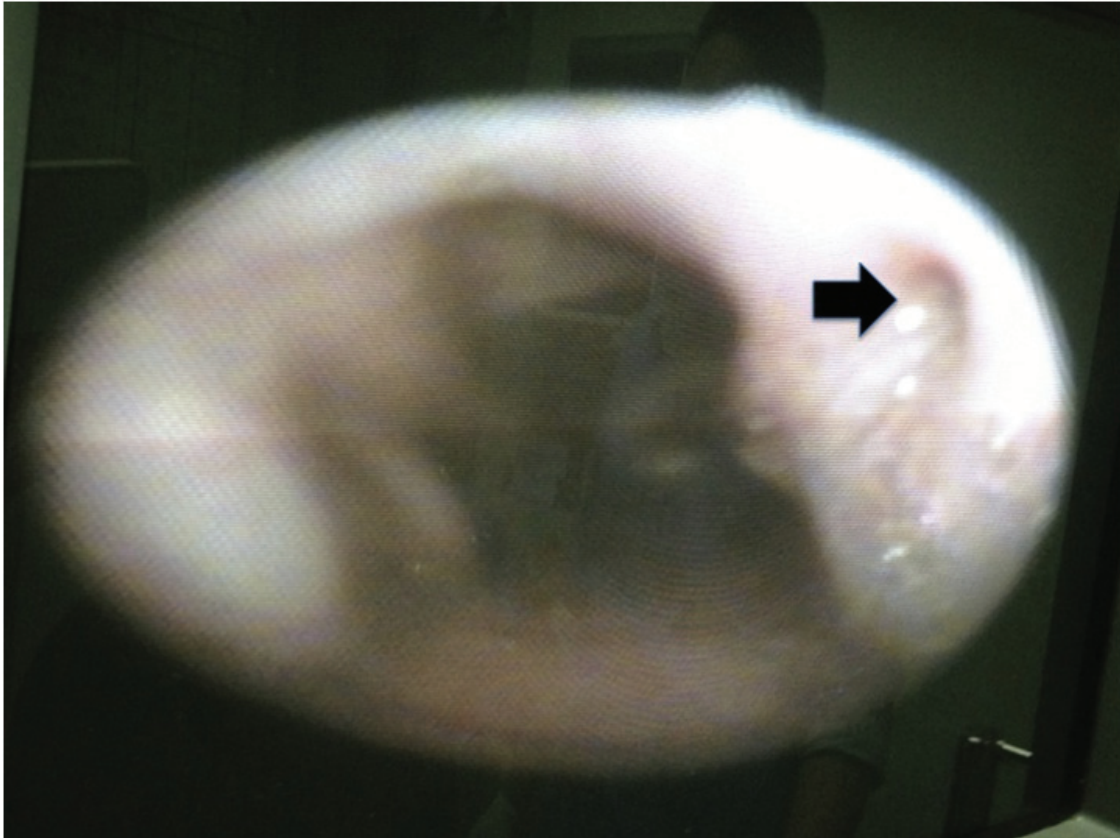


Figure 2: The esophagoscopy revealed normal appearance of the esophageal wall and a 0.5 cm esophageal fistula was detected (arrow).

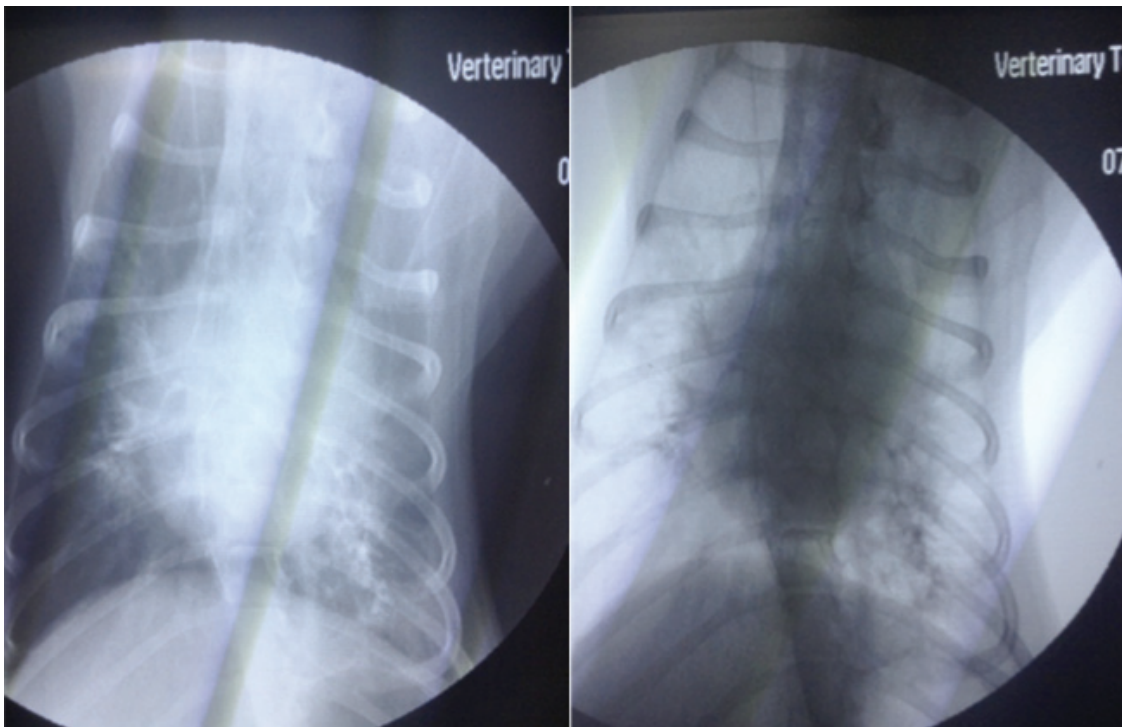


Figure 3: The contrast fluoroscopy, the barium was diffused from the esophagus to the primary bronchi of the left caudal lung lobe and some part of the right caudal lung lobe.

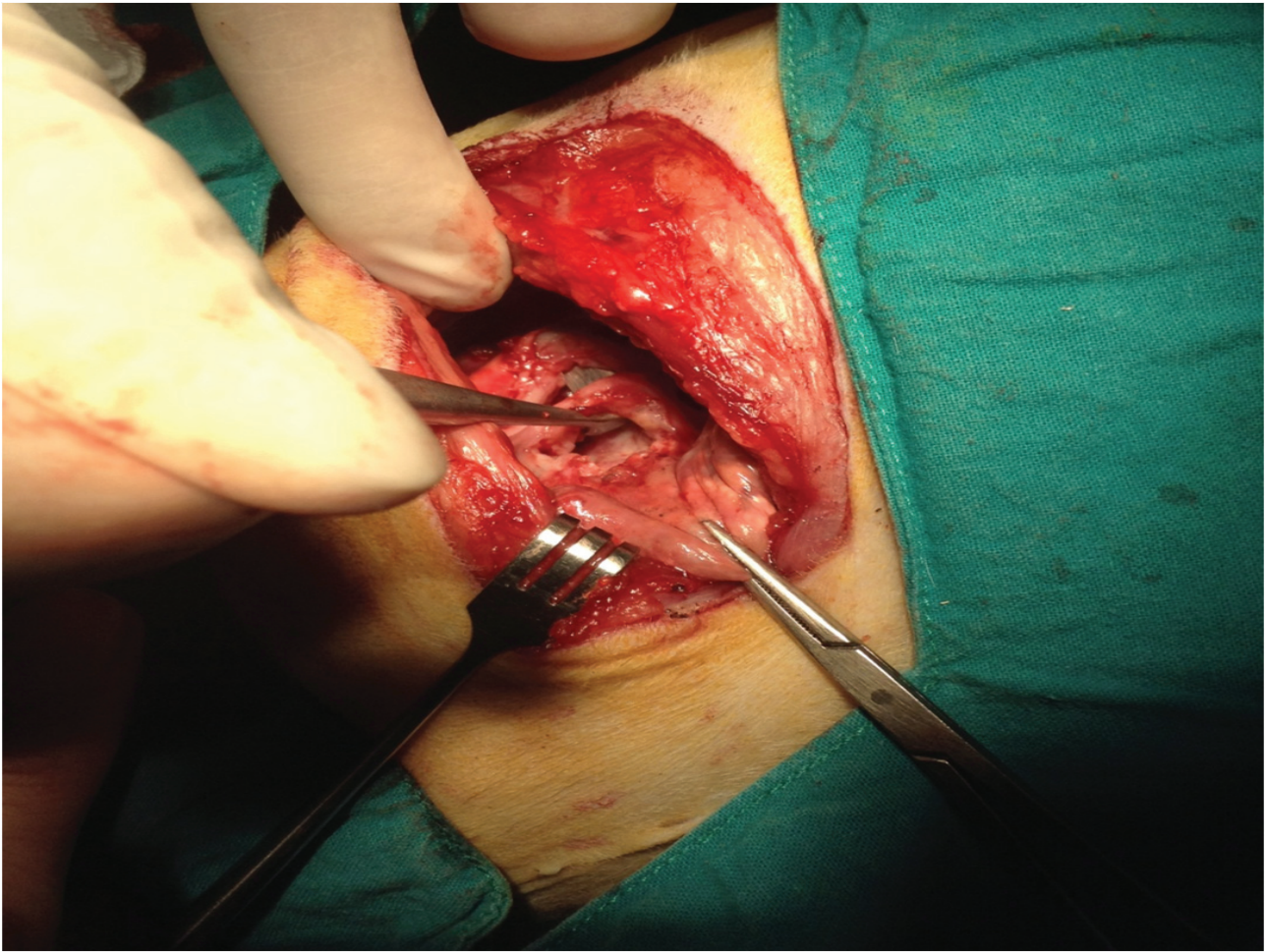


Figure 4: The thoracotomy was performed at the left chest wall in the right lateral recumbency position.

References

- Basher, A.W., Hogan, P.M., Hanna, P.E., Runyon, C.L. and Shaw, D.H. 1991. Surgical treatment of a congenital bronchoesophageal fistula in a dog. *J Am Vet Med Assoc.* 199 (4): 479-482.
- Buchanan, J.W. and Bucheler, J. 1995. Vertebral scale system to measure canine heart size in radiographs. *J Am Vet Med Assoc.* 206 (2): 194-199.
- Della Ripa, M.A., Gaschen, F., Gaschen, L. and Cho, D.Y. 2010. Canine bronchoesophageal fistulas: case report and literature review. *Compend Contin Educ Vet.* 32 (4): E1.
- Fox, S.M., Allan, F.J., Guilford, W.G., Guerin, S.R. and Cooke, M.M. 1995. Broncho-oesophageal fistula in two dogs. *N Z Vet J.* 43 (6): 235-239.
- Fruchter, O. and Dragu, R. 2003. Images in clinical medicine. A deadly examination. *N Engl J Med.* 348 (11): 1016.
- Hawkins, E.C., Boothe, D.M., Guinn, A., Aucoin, D.P. and Ngyuen, J. 1998. Concentration of enrofloxacin and its active metabolite in alveolar macrophages and pulmonary epithelial lining fluid of dogs. *J Vet Pharmacol Ther.* 21 (1): 18-23.
- Nawrocki, M.A., Mackin, A.J., McLaughlin, R. and Cantwell, H.D. 2003. Fluoroscopic and endoscopic localization of an esophagobronchial fistula in a dog. *J Am Anim Hosp Assoc.* 39 (3): 257-261.
- Parker, N.R. and Caywood, D.D. 1987. Surgical diseases of the esophagus. *Vet Clin North Am Small Anim Pract.* 17 (2): 333-358.
- van Ee, R.T., Dodd, V.M., Pope, E.R. and Henry, G.A. 1986. Bronchoesophageal fistula and transient megaesophagus in a dog. *J Am Vet Med Assoc.* 188 (8): 874-876.