

# Treatment of transitional cell carcinoma of urinary bladder using meloxicam in a dog: a case report

Kanokwan Suwankanit\* Sukanya Manee-in

Department of Clinical Sciences and Public Health, Faculty of Veterinary Science, Mahidol University, Salaya,  
Phutthamonthon, Nakhon Pathom, 73170 Thailand.

\*Corresponding author, E-mail address: kanokwan.sut@mahidol.edu

## Abstract

A 12-year-old spayed female poodle dog had clinical sign of stranguria. The dog was definitive diagnosed by radiography, ultrasonography and histopathology that it was invasive transitional cell carcinoma at the neck of urinary bladder. The dog was treated with meloxicam and black sesamin. The side effects of treatment, blood profiles and urinalysis were investigated once a month and urinary bladder ultrasonographic examination was performed every two months for disease progression monitoring. The dog had the stable size of mass. The side effects of meloxicam were not observed during treatment.

**Keywords:** transitional cell carcinoma, urinary bladder, meloxicam

# การรักษามะเร็งกระเพาะปัสสาวะในสุนัขด้วยเม็ลล็อกซิแคม

กนกวรรณ สุวรรณกนิษฐ\* สุภัฏญา มณีอินทร์

ภาควิชาเวชศาสตร์คลินิกและการสาธารณสุข คณะสัตวแพทยศาสตร์ มหาวิทยาลัยมหิดล ถนนพุทธมณฑล สาย 4  
ตำบลศาลายา อำเภอพุทธมณฑล จังหวัดนครปฐม 73170

\*ผู้รับผิดชอบบทความ E-mail address: kanokwan.sut@mahidol.edu

## บทคัดย่อ

สุนัขพันธุ์พุดเดิ้ล เพศเมียทำหมันแล้ว อายุ 12 ปี มีอาการปัสสาวะติดขัด สุนัขได้รับการวินิจฉัยยืนยันด้วยการถ่ายภาพทางรังสีร่วมกับผลการวิเคราะห์ทางเนื้อเยื่อจากการผ่าตัด ซึ่งผลการวินิจฉัยระบุพบมะเร็งกระเพาะปัสสาวะ และสุนัขตัวนี้ได้รับการรักษาทางยาคือ เม็ลล็อกซิแคม ร่วมกับงาดำ โดยสุนัขได้รับการตรวจทางโลหิตวิทยาและตรวจปัสสาวะเดือนละ 1 ครั้ง อีกทั้งได้รับการตรวจด้วยคลื่นเสียงความถี่สูงทุก ๆ 2 เดือน เพื่อทำการประเมินการดำเนินไปของโรคและผลข้างเคียงของยา ซึ่งภายหลังจากการรักษาสุนัขมีขนาดของก้อนเนื้อในกระเพาะปัสสาวะคงที่ และไม่มีผลข้างเคียงของยาเม็ลล็อกซิแคม

คำสำคัญ : มะเร็งกระเพาะปัสสาวะ กระเพาะปัสสาวะ เม็ลล็อกซิแคม

## Introduction

The lower urinary tract neoplasm is infrequently occurred in canine (Mutsaers et al., 2003; Caswell, 2011). Transitional cell carcinoma (TCC) is the most common neoplasm in canine urinary bladder (Rocha et al., 2000). Previous studies reported the increase prevalence of urinary bladder cancer in female dogs more than male dogs (Mutsaers et al., 2003; Bommer et al., 2012). Furthermore, the successful treatment of transitional cell carcinoma in the urinary bladder depends on various factors; such as the size, location and staging of cancer (Rocha et al., 2000). Mostly, a surgical excision is an effective therapeutic technique for polyps or discrete masses. Regarding the malignant mass, others adjunctive therapy should be used (Martinez et al., 2003).

Cyclooxygenase-2 (COX-2) is an inducible enzyme that changes arachidonic acid to prostaglandin in inflammatory process (Warner and Mitchell, 2004). It absents in normal cells, but it can be induced by growth factors, inflammatory reactions, tumoral promoters and oncogenes (Mutsaers et al., 2003; Baek et al., 2009; DeNardi et al., 2011). It usually expresses in epithelial carcinoma included transitional cell carcinoma in urinary bladder, skin and oral squamous cell carcinoma and mammary tumor (Mutsaers et al., 2003; Brunelle, 2006; Mohammed et al., 2006; Lee et al., 2007; Baek et al., 2009; DeNardi et al., 2011). The most studies reported that non-steroidal anti-inflammatory drugs (NSAIDs) can treat TCC in urinary bladder by inhibit COX-2 (Knapp et al., 1994; Mohammed et al., 2002; Mohammed et al., 2006; Dhawan et al., 2008; Dhawan et al., 2010; DeNardi et al., 2011; Bommer et al., 2012). Mohammed et al., (2002)

reported that piroxicam can reduce the size of tumor in 10 out of 15 dogs which decreased in tumor volume by 9-75% (partial remission 33% and stable disease 50%). The mechanism of NSAIDs which can be an antitumor effect is not complete understood, but some studies found that COX-2 inhibitor can induce the apoptosis of tumor, anti-angiogenesis in tumor and reduced in urine basic fibroblast growth factor concentration (Mohammed et al., 2002; Dhawan et al., 2008; Baek et al., 2009; DeNardi et al., 2011). NSAIDs therapy included piroxicam (Mohammed et al., 2002; Baek et al., 2009; Abbo et al., 2010; DeNardi et al., 2011), meloxicam (Bommer et al., 2012), deracoxib (McMillan et al., 2011) and firocoxib (Baek et al., 2009; Knapp et al., 2013). Deracoxib, firocoxib and meloxicam which are NSAIDs have less studied than piroxicam for treatment TCC in dogs. However, Bommer et al., (2012) studied treatment TCC by used meloxicam in cats. Additionally, NSAIDs have more side effects about gastrointestinal and renal function (Plumb and Pharm, 2008). Lipscomb et al., (1998) reported that piroxicam had more side effects than meloxicam because meloxicam caused little acute damage to the upper gastrointestinal tract but piroxicam caused gastric injury. Meloxicam is a preferential COX-2 inhibitor (not COX-2 specific) as at higher dosages it can be COX-2 specificity. It has effects to anti-inflammatory, analgesic and antipyretic activity (Baek et al., 2009). Some studies reported that it can treat TCC in urinary bladder (Plumb and Pharm, 2008; Baek et al., 2009; Bommer et al., 2012). Meloxicam was chosen in this case study because it is believed to have more selective inhibition of COX-2 over COX-1 and it has less side effects than piroxicam (Lipscomb et al., 1998).

**Case descriptions**

A 12 years old, spayed female, Poodle, body weight 6 kg, body condition score 4/5 had stranguria for 3 days with normal urine color. From the history taking, the dog had six months history of cystitis, which resolved after 14 days administration of enrofloxacin (6 mg/kg, orally, once a day). The dog usually ate vegetable. The urine sample was collected by urethral catheterization for urinalysis and bacterial culture and identification. The initial urine color was yellow, but the last stream urine color was red. Urinalysis results demonstrated hyperstenuria (USG = 1.025), basidic urine (pH = 8), proteinuria (1+), microscopic leukocyturia (50-200 cells/HPF), microscopic hematuria (10-20 cells/HPF) and bacteria in urine (rod 4+). Urine culture revealed *Escherichia coli* which was susceptible with penicillin, first generation cephalosporin, second generation cephalosporin, third generation cephalosporin, fluoroquinolone, tetracycline and aminoglycoside drugs.

Abdominal radiography (plain films) showed multiple small radio-opaque calculi in urinary bladder. Double contrast cystogram (Figure 1) demonstrated an intramural filling defect with an irregular surface at the neck of urinary bladder that protruded into the lumen of bladder. On both radiographic views, there were multiple small radiolucent calculi at center of the contrast paddle. Ultrasonography demonstrated a hyperechoic calcification mass at the neck of urinary bladder diameter 1.971.69 cm (Figure 2, A) and renal calcification at both kidney, thereafter urine sample was collected by urethral catheterization for urine cytology which revealed the loose aggregation of tumor cells which were minimal

pleomorphic, anisocytosis and anisokaryosis. Also, the nucleus of the cells had coarsely chromatin and prominent nuclei. Consequently, the result of the cytology was carcinoma (possible transitional cell carcinoma). Hematological and serum biochemical analysis revealed hyperproteinemia (9.6 g/dL; normal range: 6-7.5 g/dL) and increase alkaline phosphatase (355 U/L; normal range: 23-212 U/L).

The other hematologic variables, alanine aminotransferase, creatinine and blood urea nitrogen were in normal range. Treatment was initiated by amoxicillin with clavulanic acid (Clavamox®, SmithKline Beecham Pharmaceuticals, Philadelphia, United States of America) 20 mg/kg, orally, twice a day for 14 days and meloxicam (0.3 mg/kg, orally with food, once a day for 14 days). The diets were changed to urinary prescription diet (c/d®, Hill's Pet Nutrition Inc., Kansas, United States of America) for supporting urinary health and reduce the risk of struvite and calcium oxalate stones because it can change appropriate pH in urinary bladder for dogs.

Second week after treatment, the dog improved from stranguria. However, the mass need to diagnosis by biopsy, so the dog was cystotomy for biopsy mass in urinary bladder. Surgical approach to the bladder was caudal midline laparotomy. Before the cystotomy, the urine was collected by cystocentesis for urinalysis and bacterial culture and drug sensitivity. There were cystic calculi and two masses at the neck of urinary bladder and around urethral opening (diameter around 1 cm and 2 cm, respectively). The masses were obtained by full-thickness incisional biopsy. After surgery, the dog was received meloxicam 0.3 mg/kg, orally with food, once a day for 10

days. Urinalysis revealed hypersthenuria (USG = 1.025), acidic urine (pH = 5), microscopic leukocyturia (10-20 cells/HPF), microscopic hematuria (50-100 cells/HPF), bacteria in urine (cocci 1+) and squamous epithelial cell (2-3 cell/HPF).

One week after surgery, a urinary culture result demonstrated *Enterobacter* spp. and drug sensitivity revealed resistant to all antibiotic. The dog was then stopped to receive antibiotic. The result of the uroliths from the Minnesota Urolith Center (United States of America) was struvite. Moreover, a biopsy result demonstrated that it was invasive transitional cell carcinoma in urinary bladder (Figure 3). Thoracic radiographic finding showed no remarkable of lung metastasis. Also, the dog was final diagnosis that was stage 2 of transitional cell carcinoma in urinary bladder, no evidence of lung metastasis and lymph node metastasis, cystitis and cystic calculi. The owner decided to treat with meloxicam and bio-organic therapy. The dog was ultrasonographic examined to recheck the size of mass after surgery and check the metastasis of transitional cell carcinoma to abdominal lymph nodes. Ultrasonographic findings revealed a hyperechoic and irregular mass, which had diameter around 0.591.39 cm (Figure 2, B) at the neck of urinary bladder and no evidence of abdominal lymph nodes metastasis. The dog was monitored kidney function after NSAIDs treatment by hematological and biochemical analysis which revealed hyperproteinemia (10.4 g/dl) and increase alkaline phosphatase (375 U/L). The other hematological and biochemical variables were also within normal range. Treatment was continued with meloxicam (0.3 mg/kg,

orally with food, once a day) for treatment a TCC mass and improve life's quality of the dog because it has antitumor effect, sesamin dietary supplement (black sesame powder) for treatment TCC same as meloxicam because it can induce cell apoptosis and has an anticancer effect, and urinary prescription diet (c/d®, Hill's Pet Nutrition, Inc., Kansas, United states of America) for control pH in urinary bladder and decreased the incidence of recurrence cystic calculi. The dog's blood profiles and urinalysis were evaluated every month for health monitoring. The tumor mass size was ultrasonographic measurement every 2 months. The treatment results of meloxicam after surgery showed on table 1. The dog's clinical signs were normal. Hematological and biochemical analysis revealed hyperproteinemia and increase alkaline phosphatase. The dog had stable size of transitional cell carcinoma at the neck of urinary bladder and did not have the side effects of meloxicam.

## Discussion

In dogs, tumor in urinary bladder usually presents as invasive transitional cell carcinoma that invades into the deeper layers of the bladder wall including lamina propria and muscular layer (Mutsaers et al., 2003). In this study, the dog had invasive transitional cell carcinoma at the trigone of urinary bladder which is the most common localization of canine TCC. There are several risk factors for TCC occurring such as sex, genetic predisposition, overweight, herbicide and insecticide exposure (Mutsaers et al., 2003; Bommer et al., 2012). This dog had risk factors for TCC including; female sex and overweight because her body condition score (BCS), which range

from 1 (thin) to 5 (obese), was 4, however the etiology of this tumor is unknown. Previous studies have reported that female dogs had higher prevalence of bladder cancer than male dogs. Due to male dogs have more frequency of urination for territorial marking so it can help to decrease carcinogen containing urine contact time with the bladder epithelium. The urinary bladder mass was suspected from clinical signs because this dog had the clinical signs of stranguria and recurrent cystitis. There were many studies reported that common clinical signs of canine transitional cell carcinoma often presented similar to chronic cystitis including hematuria, dysuria, pollakiuria, and stranguria. Regarding of the recurrent cystitis that the dog should be considered to find the underlying of bladder tumor (Mutsaers et al., 2003) which is similar to this case.

Treated by meloxicam and black sesamin, this dog had cancer stage 2 because there was T2, tumor had grown into the muscle layer, N0 (no lymph node metastasis), and M0 (No distance metastasis). The dog had stable disease, <50% change in tumor volume and no new tumor lesions (Mohammed et al., 2002), when the dog was monitored by ultrasound urinary bladder for measure the size of mass every 2 months. The survival time was 920 days. NSAIDs therapy is a selective method to control TCC instead of chemotherapy and avoid undesirable effects of chemotherapy. Various studies of NSAIDs treatment in urinary bladder TCC demonstrated successful results. Abbo et al., (2010) reported 34 dogs that were given piroxicam alone resulted in median survival time (MST) of 181 days, with two complete remissions, 4 partial remissions and 18 dogs with stable disease. The TCC of dogs were treated by deracoxib and firocoxib, resulted in

MST of 323 (McMillan et al., 2011) and 152 days (Knapp et al., 2013) respectively. Meloxicam is NSAIDs which is preferential COX 2 inhibitor. It has antitumor mechanisms including induce apoptosis and anti-angiogenesis effect of tumor (DeNardi et al., 2011). Bommer et al., (2012) reported that 10 transitional cell carcinoma cats showed clinical improvement after meloxicam treatment and had MST of 311 days. Black sesamin which is phytochemical has an anticancer effect. It can suppress cell proliferation and induce cell apoptosis (Baek et al., 2009). Harikumar et al., (2010) reported that sesamin can suppress transcription factor NF- $\kappa$ B which associates with inflammation, carcinogenesis, tumor cell survival and proliferation, invasion and angiogenesis of cancer. Sesamin can support TNF- $\alpha$  to induce apoptosis of tumor cells. It can inhibit the metabolic degradation of tocotrienols so it has anti-proliferative effect in neoplastic cells (Akl et al., 2013). However, the various methods of TCC treatment including surgery, medical therapy and radiotherapy have variety of success in treatment TCC because it depends on location, size and staging of tumor (Mutsaers et al., 2003). The most location of TCC is the trigone of urinary bladder, therefore it is difficult to completely surgical remove (Mutsaers et al., 2003; Bommer et al., 2012). Radiotherapy has been rarely used in canine TCC (Mutsaers et al., 2003) due to it has many side effects such as pollakiuria, urinary incontinence and stranguria because it can cause of shrinkage of urinary bladder (Walker and Breider, 1987) and damage normal tissue (McCaw and Lattimer, 1988). Chemotherapy regimens for treatment TCC of urinary bladder consist of cisplatin; cisplatin with firocoxib; cisplatin with

piroxicam; carboplatin; carboplatin with piroxicam; doxorubicin with piroxicam in canine. There were MST of 338, 179 (Knapp et al., 2013), 124 (Knapp et al., 2000), 132, 161 (Boria et al., 2005), 168 days (Robat et al., 2013) respectively. Some chemotherapy regimens have many side effects more than NSAIDs.

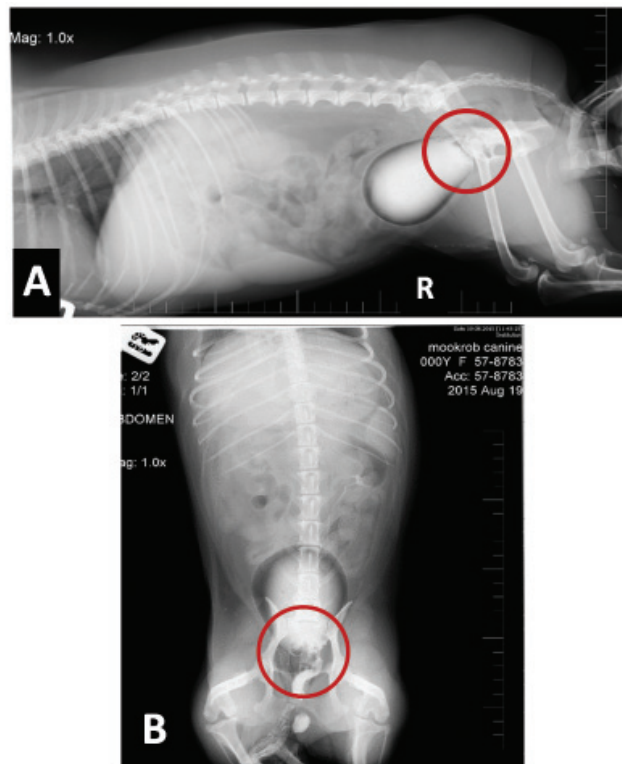
The side effects of meloxicam are the important topic to concern. Meloxicam had not side effects to this dog which was monitored clinical signs, hematological and biochemical profile, urinalysis for gastrointestinal and renal function every 1 month. The previous study demonstrated the side effects of meloxicam that caused little acute damage to the upper gastrointestinal tract. Having side effects less than piroxicam (Lipscomb et al., 1998), meloxicam is safe for long term treatment (Bommer et al., 2012).

In conclusion, meloxicam has an antitumor activity to inhibit the proliferation of cancer cells especially in this case because the dog had stable disease. Moreover, the dog had the survival time of 920 days which suggest that meloxicam may play a role to be a palliative drug of canine TCC in the urinary bladder and may be the drug of choice in this disease because it can help the dog to live longer than other chemotherapies. However, the treatment using meloxicam in dogs with TCC does not have any studies before and this report studied only one dog. Consequently, future studies with a large population of dogs which use meloxicam to treat TCC should be performed to confirm that this remedy may be successful in dogs with invasive TCC.

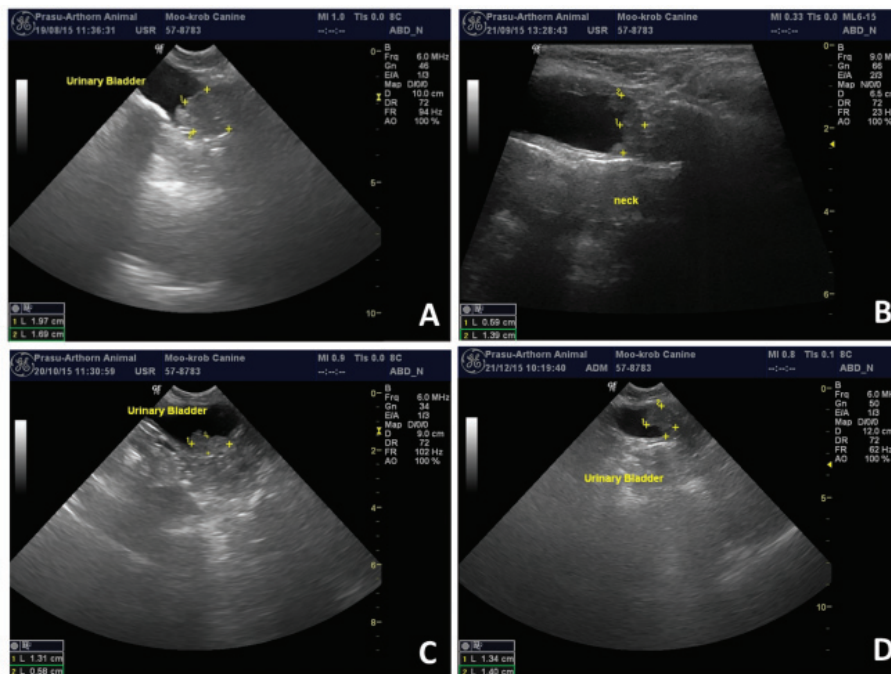
**Table 1.** Results after treatment by meloxicam

	Pre-Treatment with meloxicam	Day 34 after treatment and day 20 after surgery	Day 64 after treatment	Day 94 after treatment	Day 124 after treatment
Hematological and biochemical profiles	Hyperproteinemia (9.6g/dl), increase ALP (355 U/L)	Hyperproteinemia (10.4 g/dl), increase ALP (375 U/L)	Hyperproteinemia (9.2 g/dl), increase ALP (366 U/L)	Hyperproteinemia (9.4 g/dl), increase ALP (383 U/L)	Hyperproteinemia (9.0 g/dl)
Urinalysis	Hyperstenuria (USG = 1.025), basidic urine (pH=8), proteinuria (1+), microscopic leukocyturia (50-200 cells/HPF), microscopic hematuria (10-20 cells/HPF), bacteria in urine (rod4+)	-	Isostenuria (USG= 1.010), acidic urine (pH=5), bacteria in urine (rod3+)	Hypostenuria (USG= 1.007), acidic urine (pH=5), bacteria in urine (few cocci, rod3+)	Hyperstenuria (USG= 1.020), acidic urine (pH=5), microscopic leukocyturia (50-100 cells/HPF),microscopic hematuria (10-20 cells/HPF), bacteria in urine (few cocci, rod2+), squamous epithelial cells (1-2 cells/HPF)
Ultrasound	Hyperechoic calcification mass at the neck of urinary bladder diameter 1.97 x 1.69 cm (Figure 2, A)	TCC at the neck of urinary bladder diameter 0.59x1.39 cm (Figure 2, B)	Stable size of TCC at the neck of urinary bladder diameter 0.58 x 1.31 cm (Figure 2, C)	-	Stable size of TCC at the neck of urinary bladder diameter 1.3x1.4 cm (Figure 2, D)
Treatment outcome	-	-	Stable disease	-	Stable disease
Side effect	-	-	Not found	Not found	Not found

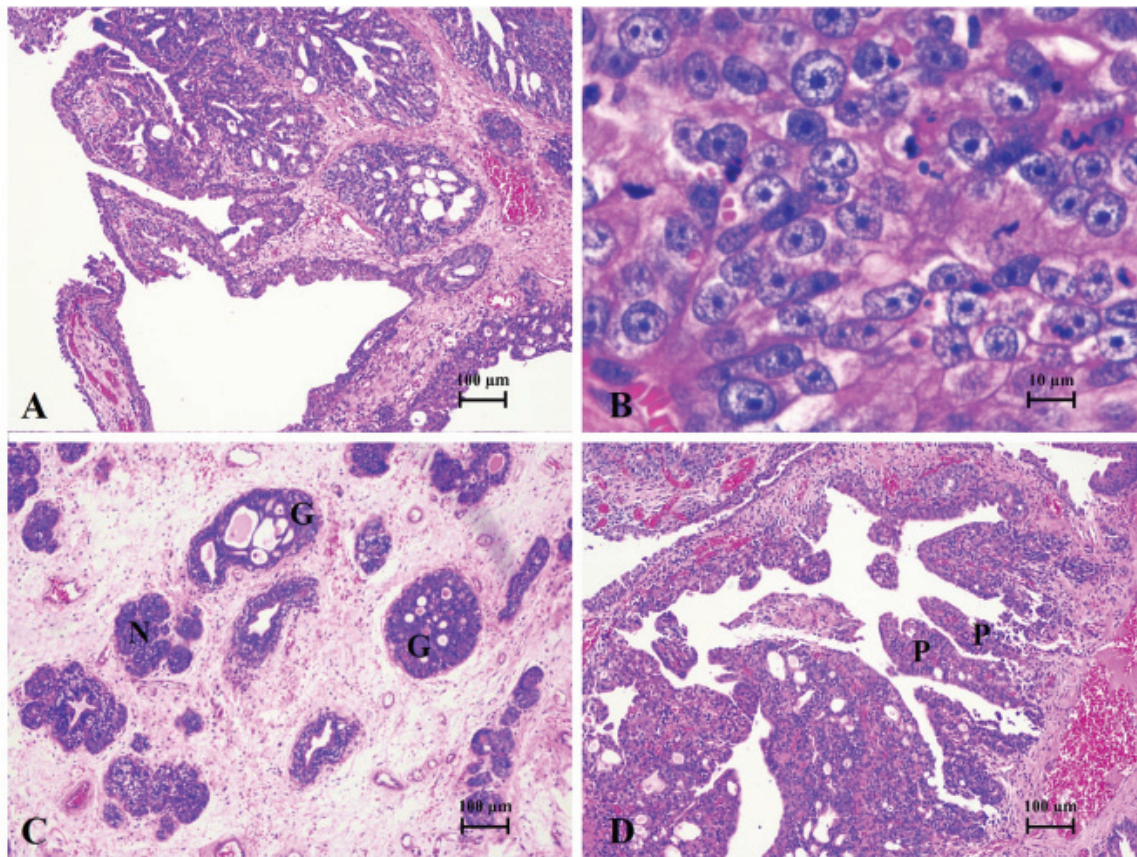
\*ALP = alkaline phosphatase, USG = Urine specific gravity, HPF = high power field, TCC = transitional cell carcinoma, cm = centimeter



**Figure 1.** The abdominal double contrast radiography. (A) Right lateral view and (B) ventrodorsal view. Double contrast cystogram showed an intramural filling defect with an irregular surface at neck of urinary bladder that protrude into the lumen of bladder. There were multiple small radiolucent calculi at center of the contrast paddle. The dog was also found mass at neck of urinary bladder (in the red circle).



**Figure 2.** (A) Pre-treatment with meloxicam, ultrasonography demonstrated hyperechoic calcification mass at neck of urinary bladder diameter 1.97x1.69 cm (marker). (B) Day 34 after treatment with meloxicam, ultrasonography demonstrated hyperechoic and irregular mass, which had diameter around 0.59x1.39 cm. (C) Day 64 after treatment, the mass at the neck of urinary bladder had diameter around 0.58x1.31 cm. (D) Day 124 after treatment, the mass had diameter around 1.34x1.4 cm.



**Figure 3.** The microscopic finding of urothelial carcinoma. (A) The neoplastic urothelial cells are invaded through the lamina propria and form diverse patterns; glandular, nest, and micropapillary (H&E, x100). (B) Cytologic criteria of malignancy are demonstrated with anisocytosis, anisokaryosis, increased nucleocytoplasmic ratio, prominent nucleoli, multiple nucleoli and mitotic figures are also presented (H&E, x1000). (C) The neoplastic urothelial cells comprised of nest (N) and glandular variant (G). Histological of nested variant is showed the large numbers of small cell, closely packed of cell, haphazardly arranged of cell that infiltrate in the lamina propria. The glandular cells structures are observed in the glandular variant of these cancer (H&E, x100). (D) The micropapillary variant (P) is established the arrangement of multiple fingers like projection in the stroma (H&E, x100).

## References

- Abbo AH, Jones DR, Masters AR, Stewart JC, Fourez L and Knapp DW. Phase I clinical trial and pharmacokinetics of intravesical mitomycin C in dogs with localized transitional cell carcinoma of the urinary bladder. *J Vet Intern Med.* 2010; 24(5): 1124-30.
- Akl MR, Ayoub NM, Abuasal BS, Kaddoumi A and Sylvester PW. Sesamin synergistically potentiates the anticancer effects of  $\gamma$ -tocotrienol in mammary cancer cell lines. *Fitoterapia.* 2013; 84: 347-59.
- Baek SJ, McEntee MF and Legendre AM. Review paper: Cancer chemopreventive compounds and canine cancer. *Vet Pathol.* 2009; 46(4): 576-88.
- Bommer NX, Hayes AM, Scase TJ and Gunn-Moore DA. Clinical features, survival times and COX-1 and COX-2 expression in cats with transitional cell carcinoma of the urinary bladder treated with meloxicam. *J Feline Med Surg.* 2012; 14(8): 527-33.
- Boria PA, Glickman NW, Schmidt BR, Widmer WR, Mutsaers AJ, Adams LG, et al. Carboplatin and piroxicam therapy in 31 dogs with transitional cell carcinoma of the urinary bladder. *Vet Comp Oncol.* 2005; 3(2): 73-80.
- Brunelle M, Sartin EA, Wolfe LG, Sirois J and Dore M. Cyclooxygenase-2 expression in normal and neoplastic canine mammary cell lines. *Vet Pathol.* 2006; 43: 656-66.
- Caswell M. Transitional cell carcinoma of the urinary bladder in a 14-year-old dog. *Can Vet J.* 2011; 52(6): 673-5.
- DeNardi AB, Raposo TM, Huppes RR, Daleck CR and Amorim RL. Cox 2 inhibitors for cancer treatment in dogs. *Pak Vet J.* 2011; 31(4): 275-9.
- Dhawan D, Craig BA, Cheng L, Snyder PW, Mohammed SI, Stewart JC, Zheng R, Loman RA, Foster RS and Knapp DW. Effects of short-term celecoxib treatment in patients with invasive transitional cell carcinoma of the urinary bladder. *Mol Cancer Ther.* 2010; 9(5): 1371-7.
- Dhawan D, Jeffreys AB, Zheng R, Stewart JC and Knapp DW. Cyclooxygenase-2 dependent and independent antitumor effects induced by celecoxib in urinary bladder cancer cells. *Mol Cancer Ther.* 2008; 7(4): 897-904.
- Harikumar KB, Sung B, Tharakan ST, Pandey MK, Joy B, Guha S, et al. Sesamin manifests chemopreventive effects through the suppression of NF-kappa B-regulated cell survival, proliferation, invasion, and angiogenic gene products. *Mol Cancer Res.* 2010; 8(5): 751-61.
- Knapp DW, Glickman NW, Widmer W, DeNicola D, Adams L, Kuczek T, et al. Cisplatin versus cisplatin combined with piroxicam in a canine model of human invasive urinary bladder cancer. *Cancer Chemother Pharmacol.* 2000; 46(3): 221-6.
- Knapp DW, Henry CJ, Widmer WR, Tan KM, Moore GE, Ramos-Vara JA, et al. Randomized trial of cisplatin versus firocoxib versus cisplatin/firocoxib in dogs with transitional cell carcinoma of the urinary bladder. *J Vet Intern Med.* 2013; 27(1): 126-33.

- Knapp DW, Richardson RC, Chan TCK, Bottoms GD, Widmer WR, DeNicola DB, et al. Piroxicam therapy in 34 dogs with transitional cell carcinoma of the urinary bladder. *J Vet Intern Med.* 1994; 8(4): 273-8.
- Lee JY, Tanabe S, Shimohira H, Kobayashi Y, Oomachi T, Azuma S, et al. Expression of cyclooxygenase-2, P-glycoprotein and multi-drug resistance-associated protein in canine transitional cell carcinoma. *Res Vet Sci.* 2007; 83(2): 210-6.
- Lipscomb GR, Wallis N, Armstrong G and Rees WDW. Gastrointestinal tolerability of meloxicam and piroxicam: a double-blind placebo-controlled study. *Br J Clin Pharmacol.* 1998; 46(2): 133-7.
- Martinez I, Mattoon JS, Eaton KA, Chew DJ and DiBartola SP. Polypoid cystitis in 17 dogs (1978-2001). *J Vet Intern Med.* 2003; 17(4): 499-509.
- McCaw DL and Lattimer JC. Radiation and cisplatin for treatment of canine urinary bladder carcinoma. *Vet Radiol.* 1988; 29(6): 264-8.
- McMillan SK, Boria P, Moore GE, Widmer RW, Bonney LP and Knapp DW. Antitumor effects of deracoxib treatment in 26 dogs with transitional cell carcinoma of the urinary bladder. *J Am Vet Med Assoc.* 2011; 239(8): 1084-9.
- Mohammed SI, Bennett PF, Craig BA, Glickman NW, Mutsaers AJ, Snyder PW, et al. Effects of the cyclooxygenase inhibitor, piroxicam, on tumor response, apoptosis, and angiogenesis in a canine model of human invasive urinary bladder cancer. *Clin Cancer Res.* 2002; 62: 356-8.
- Mohammed SI, Dhawan D, Abraham S, Snyder PW, Waters DJ, Craig BA, et al. Cyclooxygenase inhibitors in urinary bladder cancer: in vitro and in vivo effects. *Mol Cancer Ther.* 2006; 5(2): 329-36.
- Mutsaers AJ, Widmer WR and Knapp DW. Canine transitional cell carcinoma. *J Vet Intern Med.* 2003; 17(2): 136-44.
- Robat C, Burton J, Thamm D and Vail D. Retrospective evaluation of doxorubicin-piroxicam combination for the treatment of transitional cell carcinoma in dogs. *J Small Anim Pract.* 2013; 54(2): 67-74.
- Rocha TA, Mauldin GN, Patnaik AK and Bergman PJ. Prognostic factors in dogs with urinary bladder carcinoma. *J Vet Intern Med.* 2000; 14(5): 486-90.
- Walker M and Breider M. Intraoperative radiotherapy of canine bladder cancer. *Vet Radiol.* 1987; 28(6): 200-4.
- Warner TD and Mitchell JA. Cyclooxygenases: new forms, new inhibitors, and lessons from the clinic. *FASEB J.* 2004; 18(7): 790-804.