

Brunner's Gland Adenoma: A Report of Two Cases

Panjai Woharndee, MD*,
Pattana Sornmayura, MD*, Sukhum Bunyaratvej, MD*

* Department of Pathology, Faculty of Medicine, Ramathibodi Hospital, Mahidol University

Brunner's gland adenoma is a very rare benign tumor of the duodenum. Only two cases of the adenoma have been in the file of the surgical pathology unit of Ramathibodi Hospital since 1992 and presented in this communication. The tumor is capable of producing a variety of clinical manifestations. Presently, endoscopic study plays an important role in both detection and diagnostic biopsy. Local excision, either by endoscopy or surgery is the main treatment in symptomatic cases. Ductal malignancy on top of Brunner's gland adenoma was described in one from estimated 200 recorded cases in the English literature since 1835.

Keywords: Brunner's gland adenoma, Brunner's gland hamartoma, Brunneroma

J Med Assoc Thai 2005; 88(6): 841-4

Full text. e-Journal: <http://www.medassocthai.org/journal>

Benign tumor of duodenal Brunner's gland was first described in 1835⁽¹⁾ and recognized to contribute only 1 case (2%) in 50 cases of benign and malignant tumors of the small intestine i.e. duodenum, jejunum and ileum in a General hospital of Boston⁽²⁾. Presently, less than 200 cases have been described in the English literature⁽³⁾ with synonymous terms including Brunner's gland adenoma (BGA)⁽³⁻¹⁷⁾, Brunner's gland hamartoma⁽¹⁸⁻²⁰⁾ or Brunneroma^(21,22). BGA's have been found in both sexes, commonly 40-60 years of age⁽¹⁾. Depending on tumor size and location, BGA may cause a variety of symptoms in 52% of cases⁽⁴⁾, including abdominal pain, dyspepsia, nausea, vomiting and upper gastrointestinal bleeding presenting as melena or hematuria, and rarely watery diarrhea⁽¹⁴⁾. Since 1992, two cases of BGA could be searched from the file of our surgical pathology unit, with laboratory routine consisting of 15,000 specimens by average per year. One patient developed melena due to a bleeding antral ulcer and another due to duodenal obstruction.

Case Report

Case 1

A 46-year-old Thai man, with a four-year history of hypertension, treated by calcium-channel

blocker, developed several episodes of melena, for 10 days before admission. By endoscopy, a bleeding small ulcer at the gastric antrum and a pedunculated polypoid mass in the anterior aspect of the first part of the duodenum were observed. Laboratory investigations included hemoglobin of 11.9 g%; hematocrit 37% and positive occult blood in stool. Other necessary laboratory values were within normal limits. The patient was treated by H2-blocker for his antral ulcer.

Four weeks later, repeated esophagogastros-copy showed a healed gastric ulcer and the same duodenal mass. The tumor was resected by laparotomy with antrectomy and first-part duodenectomy. Truncal vagotomy and Billroth II procedure were performed. On gross examination, the lesion was a circumscribed pedunculated mass measuring 4 x 3.5 x 3 cm with a thick stalk measuring 0.5 cm. in length from the mucosal surface (Fig. 1). The polyp was covered with mucosa similar to the surrounding mucosa. Cut surface of the polyp revealed gray-white soft tissue with small cysts averaging 1-5 mm in diameter containing clear fluid. Microscopically, the tumor was nonencapsulated and consisted of closely packed acinotubular Brunner's glands, lined by cuboid-to-columnar cells with clear cytoplasm⁽²³⁾ and dilated ducts (Fig. 2). The patient had an uneventful postoperative course. He had regular hospital visits with no episode of recurrent tumor 2¹/₂ years after his operation.

Correspondence to : Woharndee P, Department of Pathology, Faculty of Medicine, Ramathibodi Hospital, Mahidol University, Bangkok 10400, Thailand.

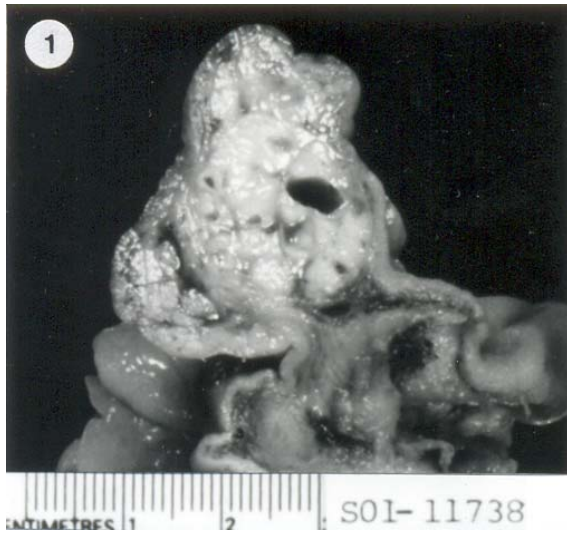


Fig. 1 Cut surface of the Brunner's gland adenoma, showing lobulated grey-white appearance with occasional cystic dilatation of the ducts, 1-5 mm in diameter

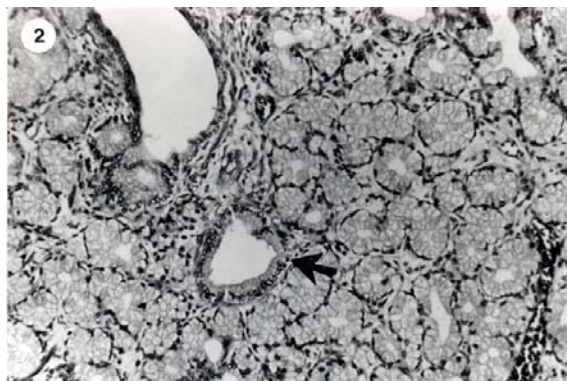


Fig. 2 Microscopically, clear cells lining tubuloacinar glands are seen mainly. Occasional ducts lined by cuboid cell are observed (arrow). Hematoxylin and eosin X130

Case 2

A 48-year-old Thai woman was admitted to the hospital with complaints of epigastric fullness and frequent nausea and vomiting for 1 month due to obstruction of the pyloric canal. Subtotal gastrectomy with Billroth II anastomosis was performed. Grossly, the stomach was dilated with marked edema of the wall. There was an ill-defined submucosal mass measuring 3 x 2.5 x 2.5 cm located at the antrum. On cut surfaces, the lesion was round and unencapsulated with homogeneous gray-white soft tissue with small cysts containing clear fluid. Microscopic examination of the mass revealed features similar to those in the first case. Postoperative course was uneventful 2 months after the operation.

Discussion

Histologically, Brunner's glands are branched acinotubular glands located in submucosa and lined with cuboid-to-columnar clear cells in the glands and cuboid cells in the duct. These glands empty their excretory fluid into the crypts of Lieberkuhn in the duodenum. Brunner's gland distribution is mostly proximal to the ampulla of Vater and distal to the pylorus. Brunner's gland heterotopia commonly occurs in the antrum⁽²⁴⁾. In infants, these glands in the duodenum are more abundant than in adults⁽²⁵⁾. Functionally, the glands excrete alkaline fluid to neutralize HCl from the stomach and secrete a hormonal enterogastrone to inhibit gastric acid excretion⁽¹⁴⁾.

Overgrowth of Brunner's glands forming a tumor larger than 1 cm in diameter is referred to as BGA, and less than 1 cm as Brunner's gland hyperplasia⁽²⁶⁾. Pathogenesis of BGA is inconclusive, and is unlikely to be secondary to gastric hyperacidity^(4,6), whereas inflammation remains as a causal possibility⁽⁴⁾. Grossly, BGA may be seen as a pedunculated polypoid lesion as in case 1 or sessile as in case 2⁽¹⁴⁾. BGA occur most frequently in the duodenal bulb, and the largest recorded was 12x10x8 cm⁽¹⁸⁾. Differential diagnosis includes gastrointestinal stromal tumor, benign and malignant, (previously known as gastrointestinal leiomyoma and leiomyosarcoma)⁽²⁷⁾, lipoma, endocrine cell tumor (carcinoid tumor), lymphoma, vascular tumor, aberrant pancreatic tissue, adenocarcinoma, adenomatous polyp, prolapsed pyloric mucosa, ampullary neoplasm and even a foreign object⁽¹⁴⁾. Definite diagnosis can be obtained only by histopathological method.

Investigation by either barium enema, ultrasonography, computerized tomography and magnetic resonance imaging are capable of localizing the tumor. Endoscopic study is imperative in performing biopsy for histopathological examination. More than 99% of BGAs are benign lesions, however, some recent reports described dysplasia with high proliferative potential according to MIB-1 positivity and early ductal malignancy arising in BGA^(16,28), as well as endocrine cell differentiation (carcinoid) of this tumor⁽¹⁹⁾.

BGA was considered to be hamartoma not neoplasm^(3,16) with predominance of Brunner's gland element along with mixture of smooth muscle, adipose tissue, Paneth cells and mucosal glands. Ductal malignancy arising from BGA reported in 1 case⁽²⁸⁾ should represent a secondary process on top of the hamartomatous one occurring prior under a very rare circumstance of one in 200 cases or 0.5%.

Endoscopic or surgical removal of BGA has been suggested in symptomatic patients by considering size and gross appearance⁽¹⁴⁾. Endoscopic snare-cautery techniques is more cost-effective, less invasive than abdominal surgery and offers no risks of the surgery. However, particular anatomical location may not allow possible endoscopic removal.

References

1. Cruveilhier J. Anatomy of the human body. New York, NY: Harper and Bros, 1844.
2. Botsford TW, Crowe P, Crocker DW. Tumours of the small intestine. *Am J Surg* 1962; 103: 358-62.
3. Yadav D, Hertan H, Pitchumoni CS. A giant Brunner's gland adenoma presenting as gastrointestinal hemorrhage. *J Clin Gastroenterol* 2001; 32: 448-50.
4. de Castella. Brunner's gland adenoma, an unusual cause of intestinal bleeding. *Br J Surg* 1966; 53: 153-6.
5. Appel MF, Bentlif PS. Endoscopic removal of bleeding Brunner's gland adenoma. *Arch Surg* 1976; 111: 301-2.
6. Peison B, Benisch B. Brunner's gland adenoma of the duodenal bulb. *Am J Gastroenterol* 1982; 77: 276-8.
7. Kehl O, Buhler H, Stamm B. Endoscopic removal of a large, obstructing and bleeding duodenal Brunner's gland adenoma. *Endoscopy* 1985; 17: 231-2.
8. Khawaja HT, Deakin M, Colin-Jones DG. Endoscopic removal of a large ulcerated Brunner's gland adenoma. *Endoscopy* 1986; 18: 199-201.
9. Zhang SY. Duodenal Brunner's gland adenoma: a report of 2 cases. *Zhonghua Wai Ke Za Zhi* 1990; 28: 390-1,444.
10. Contreras MF, Robledo AMC, Sola GI. Adenoma of Brunner's glands. *Rev Esp Enferm Dig* 1991; 79: 153-5.
11. Muezzinoglu B, Ustun H, Demirhan B. Brunner's gland adenoma: case report. *N Z Med J* 1995; 108: 14.
12. Rey P, Mambrini P, Barthet M. Adenoma of Brunner's gland: a rare cause of duodenal obstruction. *J Chir (Paris)* 1996; 133: 162-6.
13. Rhiner R, Meyenberg A, Aeberhard P. Large Brunner's adenoma of the duodenal bulb - a case report. *Swiss Surg* 1997; 3: 13-6.
14. Adeonigbagbe O, Lee C, Karowe M. A Brunner's gland adenoma as a cause of anemia. *J Clin Gastroenterol* 1999; 29: 193-6.
15. Cavallaro G, Albanese V, Taranto F. Brunner's adenoma, esophageal reflux and gastric ulcer. A case report. *Chir Ital* 2000; 52: 703-6.
16. Fujimaki E, Nakamura S, Sugai T. Brunner's gland adenoma with a focus of p53-positive atypical glands. *J Gastroenterol* 2000; 35: 155-8.
17. Jansen JM, Stuijbergen WN, van Milligen de Wit AW. Endoscopic resection of a large Brunner's gland adenoma. *Neth J Med* 2002; 60: 253-5.
18. Desilva S, Chandrasoma P. Giant duodenal hamartoma consisting mainly of Brunner's glands. *Am J Surg* 1977; 144: 240-3.
19. Matsui T, Iida M, Fujischima M, Sakamoto K, Watanabe H. Brunner's gland hamartoma associated with microcarcinoids. *Endoscopy* 1989; 21: 37-8.
20. Levine JA, Burgart LJ, Batts KP, Wang KK. Brunner's gland hamartoma: clinical presentation and pathological features of 27 cases. *Am J Gastroenterol* 1995; 90: 290-4.
21. Bastlein C, Decking R, Voeth C, Ottenjann R. Great Brunneroma of the duodenum. *Endoscopy* 1988; 20: 154-5.
22. Tan YM, Wong WK. Giant brunneroma as an unusual cause of upper gastrointestinal hemorrhage: report of a case. *Surg Today* 2002; 32: 910-2.
23. Sternberg SS. Duodenum. In: *Histology for pathologists*. Pennsylvania: Lippincott-Raven, 1991: 557-60.
24. Chandrasoma P. *Gastrointestinal pathology*, Connecticut: Appleton and Lange, 1999: 133-4.
25. Fuller JW, Maj MC, Cruse CW, William JW. Hyperplasia of Brunner's glands of the duodenum. *Am Surg* 1997; 43: 246-50.
26. Peetz ME, Moseley HS. Brunner's gland hyperplasia. *Am Surg* 1989; 55: 474-7.
27. Hamilton SR, Aaltonen LA. WHO classification of tumours. Pathology and genetics tumours of the digestive system. France: IARC Press, 2000.
28. Zanetti G, Casadei G. Brunner's gland hamartoma with incipient ductal malignancy: report of a case. *Tumori* 1981; 67: 75-8.
29. Rubio CA. Rare and secondary (metastatic) tumors. In: Whitehead R, ed. *Gastrointestinal and oesophageal pathology*, second ed. Edinburgh: Churchill Livingstone, 1995: 836-46.

เนื้องอกชนิดไม่ร้ายของต่อมบรูเนอรัส : รายงานผู้ป่วย 2 ราย

ปานใจ ไหวหารดี, พัฒนา ศรีมยุรา สุขุม บุญยะรัตเวช

อดีโนมาของต่อมบรูเนอรัสเป็นเนื้องอกชนิดไม่ร้ายของลำไส้เล็กส่วนต้นดูโอดีนัม คณะผู้รายงานได้นำเสนอผู้ป่วยสองรายที่มีอดีโนมาชนิดนี้จากการวินิจฉัยโดยภาควิชาพยาธิวิทยา ตั้งแต่ปีค.ศ. 1992 เนื้องอกชนิดนี้สามารถทำให้เกิดอาการทางคลินิกได้หลากหลาย การตรวจด้วยกล้องส่องทางเดินอาหาร มีบทบาทสำคัญในการตรวจพบและการตัดชิ้นเนื้อเพื่อการวินิจฉัย การเอาก้อนออกโดยทางกล้องส่องทางเดินอาหาร หรือ การผ่าตัดหน้าท้องเป็นการรักษาหลัก ในผู้ป่วยที่มีอาการะเร็งเกิดขึ้นกับอดีโนมาของต่อมบรูเนอรัสพบได้หนึ่งภายในจำนวนผู้ป่วย 200 ราย ในรายงานที่เป็นภาษาอังกฤษตั้งแต่ปีค.ศ. 1835
