



Thermally Oxidized Olive Oil Produces Biochemical, Physiological Effects and Fatty Liver in Rats

Ayaz Ali Khan [a], Alam Zeb* [a] and Syed Tufail Hussain Shirazi [b]

[a] Department of Biotechnology, University of Malakand, Chakdara, Pakistan.

[b] National Centre of Excellence in Analytical Chemistry, University of Sindh, Jamshoro, Pakistan.

*Author for correspondence; e-mail: Alamzeb01@yahoo.com

Received: 13 July 2015

Accepted: 28 September 2015

ABSTRACT

This study was aimed to determine the toxic effects produced by thermally oxidized olive oil under specified conditions in rats. Olive oil was thermally oxidized at 100 °C. The olive oil samples were analysed for fatty acid composition using GC-MS. The oxidized olive oil was fed to the rats at the rate of 1, 2 and 3 g/kg body weight for 30 days. The blood samples were analysed for haematological and biochemical parameters, while the liver was studied for histology. Results showed that the supplementation of oxidized olive oil significantly affected biochemical and haematological parameters. Oxidized olive oils contributed significantly to the development of atherogenesis in rats. The most affected was male rats as compared to the female rats. Histological studies of liver showed the development of fatty infiltration with reactive and enlarged Kupffer's cells. Supplementation of thermally oxidized olive oil promotes fatty infiltration and atherosclerosis in rats.

Keywords: oxidized olive oil, atherogenesis, rat liver, plasma lipids, hematology, histology

1. INTRODUCTION

Olive oil is one of the most widely used edible oil in the Mediterranean countries. The extensive uses are attributed to the several important components present in the olive oil and the health promoting properties [1]. Olive oil contains various important phenolic compounds beneficial for health [2]. However, triacylglycerol (TAG) constitute the major part of all types of olive oil. The fatty acid present in triacylglycerol includes a high amounts of oleic acid (68-83%), palmitic acid (P) 8-16%, stearic acid (S) 1.7-3.0%, linoleic acid (L) 5-13% and a small amount of myristic

acid (M) [1]. The important triacylglycerols include MOP, MOS, POP, SOS, POP, SOP, LOO, OLO, POO, SOO, PLP, SLP, OOO, POL, SOL, MLO, PLO, and SLO [3, 4]. Due to the presence of various natural antioxidants, the olive oil is considered as one of the best edible oils in term of usage and beneficial properties. For example Lipworth et al. [5] hypothesized that olive oil does not promote cancer similar to other fats. Olive oil phenols have been found to be linked those processes which contribute to the pathogenesis of heart disease and also cancer.

Similarly, olive oil hydroxytyrosol effectively protected human erythrocytes against the oxidative stress produced by hydrogen peroxide [6]. Recently Farras et al. [7] showed that polyphenols from olive oil exert an *in-vivo* nutri-genomic effect on genes related to cholesterol efflux in humans.

These beneficial properties of the olive oil are lost or reduce to negligible levels, when the oil is thermally oxidized during frying. Previous studies also suggest a relatively higher toxicity in Wister rats of the diet containing 15 % oxidized olive oil distillate as compared to the same of the oxidized corn oil [8]. These authors proposed that it may be due to the higher tocopherol content of the corn oil. Similarly, the treatment of the heart endothelial cultured cells with oxidized corn oil or oxidized olive oil, showed a lower amounts of the linoleic and arachidonic acids in the phospholipid moieties compared to the controls [9]. There is, however, limited information is available regarding the thermally oxidized olive oil on the atherosclerosis and toxic effects produced in serum biochemistry, histology and haematological indices in experimental animal models. In order to study the above mentioned parameters, thermally oxidized olive oil was administered orally to the rats for a specific period. Serum biochemical parameters, haematological parameters and histology were affected significantly.

2. MATERIALS AND METHODS

2.1 Materials

Olive oil was purchased from the local market at Chakdara, Lower Dir. Standard glucose and cholesterol was purchased from Sigma Aldrich (Germany). All other chemicals and reagents were of ACS analytical grade from Sigma Aldrich (USA) or otherwise mentioned.

2.2 Thermal Oxidation

Olive oil was thermally oxidized on hot plate at 100 °C, for consecutively for 5, 10 and 15 hours. At the end, oil samples were stored in a refrigerator at -20 °C till the initiation of administration.

2.3 Characterization of Olive Oil

The peroxide value (PV), anisidine value (AV) and free fatty acids (FFA) of the un-oxidized and oxidized olive oils were determined using the AOCS methods [10]. Total phenolic compounds in the different oil samples were determined using Folin-Ciocalteu reagent [11]. Fatty acids as fatty acid methyl ester (FAMES) were analysed using gas chromatography coupled with mass spectrometric detection (Agilent 5975, Agilent Germany) [12]. Fatty acids of the oil samples were identified from their relative as well as absolute retention times and also by the MS library database. The values were expressed as % obtained from the peak area. The radical scavenging assays (RSA) of the oil samples were measured with the help of DPPH free radicals [13]. The RSA toward DPPH radicals was calculated from the following formula:

$$\text{Radical scavenging activity (\%)} = (\text{Ac-As}/\text{Ac}) \times 100$$

2.4 Experimental Animals & Feeding

All experiments were carried out according to the approved guidelines of the Department of Biotechnology, University of Malakand, for the care and proper use of the animals. Wister rats were obtained from National Institute of Health (NIH), Islamabad. At start of the experiments, rats were almost two months old. Both the male (M) and female (F) rats were randomly divided into four groups in replicates, while two groups from each gender were kept as control.

The coding for these groups were MC (male control), FC (female control), M1 (male fed with 1 g/kg bwt dose), F1 (female fed with 1 g/kg bwt dose), M2 (male fed with 2 g/kg bwt dose), F2 (female with 2 g/kg bwt dose), M3 (male with 3 g/kg bwt dose) and F3 (female with 3 g/kg bwt dose) based on the gender. Rats having approximately same weights were kept in the same group. The treated groups were fed with 1, 2 and 3 g/kg of oxidized olive oil for 30 days. The animals had free access to their food and water throughout the entire study period. All animals were placed one week ahead to get familiarized with the environment. The composition of the basal casein diet was casein 22%, sucrose 69.5%, corn oil 4.5%, salt mixture IV 4.0%. The animals were sacrificed after completion of feeding time. The blood samples were collected in falcon tubes and centrifuge to obtain serum for further analysis.

2.5 Serum Biochemistry & Atherogenic Indices

Biochemical parameters of the serum such as cholesterol, triacylglycerol, HDL-cholesterol, ALT, and glucose were measured using HUMAN (Germany) kits. The LDL-cholesterol was determined using Friedewald equation [14]. The atherogenic indices such as cardiac risk ratio, atherosclerosis index and atherogenic index of plasma were determined using equations of Ikewuchi et al. [15].

2.6 Histo-pathological Studies of Liver

A section of the collected liver was dissected and fixed in a 10 % formalin buffer for 14 h. The sections were dehydrated with ethanol solutions. Sections of about 10 mm in thickness were cut out, deparaffinized, then rehydrated and stained [16]. The prepared slides were studied by electric microscope

(model M 7000 D series, Swift Instruments Inc, Japan). The pictures were documented help of a digital camera (DCM 130) of the microscope having resolution of 1.3 MP.

2.7 Haematological Studies

For haematological examination, 2 mL blood was collected in EDTA tubes. Haematology was studied out by automatic digital machine (CELL-DYN 3200 Abbott Diagnostic Division, Canada). The haematological parameters like Blood Haemoglobin Level (Hb), Blood Total RBC Level (RBC), Blood HCT Level (HCT %), Mean Corpuscular Volume (MCV), Mean Corpuscular Haemoglobin (MCH), Blood Platelets Concentration, and Blood White blood cell Concentration were studied.

2.8 Statistical Analysis

The data obtained were analysed using one-way analysis of variance (ANOVA) and Holm-Sidak method of multiple comparison method with help of Sigma Plot for windows version 12.3 (Systat Software, Inc, 2012).

3. RESULTS

3.1 Characterization of Olive Oil

The total phenolic contents (TPC) in non-oxidized olive oil was 2.82 ± 0.2 mg of GAE /g, was significantly reduced to 1.62 ± 0.05 , 1.37 ± 0.08 and 0.93 ± 0.10 mg of GAE /g (SD \pm mean) in oil samples heated for 5, 10 and 15 hours respectively as shown in Table 1. The PV of the control (0.93 ± 0.05 meq/kg) increases significantly ($P < 0.05$) to 4.61 ± 0.10 , 6.1 ± 0.10 , and 11.3 ± 0.20 meq/kg (mean \pm SD) respectively. Similarly AV also increases significantly ($p < 0.05$) from 6.90 ± 0.30 of the control to 12.98 ± 0.10 , 19.46 ± 0.60 and 25.4 ± 0.50 for 5, 10 and 15 h treatments respectively. The free fatty acid contents of non-oxidized olive oil was 0.12 ± 0.17 % (mean \pm SD) increased

significantly ($P < 0.05$) to 3.0 ± 0.15 %, 4.47 ± 0.30 % and 7.4 ± 0.17 %, in oil samples heated for 5, 10 and 15 hours respectively. The RSA values of the non-oxidized olive oil and oxidized olive oils were 59.43 ± 0.80 %, 36.30 ± 0.50 % (5 h), 29.22 ± 0.50 % (10 h) and 22.86 ± 0.55 % (15) respectively. The RSA values of the oxidized olive oils were reduced significantly ($P < 0.05$) after thermal oxidation.

Table 1 shows the major fatty acid

composition of un-oxidized and oxidized olive oils. It was observed that olive oil was rich in oleic acid (C18:1), with no significant changes occurred during oxidation. The composition of linoleic acid (C18:2) decreased significantly from the control to the 15 h treatment. No significant changes were observed in stearic acid (C18:0) and palmitic acid (C16:0).

Table 1. Characterization and fatty acids composition of un-oxidized and oxidized olive oils.

Sample	PV (meq/kg)	AV	FFA (%)	TPC (mg/g)	RSA (%)	Fatty Acids (%) [*]			
						C16:0	C18:0	C18:1	C18:2
Control	$0.93^a \pm 0.05$	$6.9^a \pm 0.35$	$0.12^a \pm 0.17$	$2.82^a \pm 0.2$	$59.43^a \pm 0.80$	7.7	3.6	77.9	5.0
5 h	$4.6^b \pm 0.10$	$12.98^b \pm 0.14$	$3.0^b \pm 0.15$	$1.62^b \pm 0.04$	$36.30^b \pm 0.50$	6.9	3.1	83.4	3.3
10 h	$6.1^c \pm 0.10$	$19.46^c \pm 0.60$	$4.47^c \pm 0.30$	$1.36^c \pm 0.08$	$29.22^c \pm 0.50$	5.4	2.8	89.9	2.8
15 h	$11.3^d \pm 0.20$	$25.4^d \pm 0.50$	$7.4^d \pm 0.17$	$0.93^d \pm 0.1$	$22.86^d \pm 0.50$	8.4	3.6	81.4	2.0

Values are expressed as Mean \pm SD of $n=3$. Mean with different subscript letters (a-d) differ significantly ($p < 0.05$). PV, peroxide value; AV, anisidine value; FFA, free fatty acids; TPC, total phenolic contents; RSA, radical scavenging activity. * Values expressed are the percent composition (%) obtained from the percent peak area of GC-MS chromatogram of the respective sample.

3.2 Effects on The Serum Biochemistry

There was no significant difference of the total cholesterol among the male and female control who were not fed with olive oil (131.75 mg/dL of male and 123.52 mg/dL of female). There was significant ($p < 0.001$) increase in male rats fed with oxidized olive oil at a dose rate of 1, 2 and 3 g/kg bwt (152.28, 174.55 and 194.04 mg/dL). In female rats, there was no significant increase at the dose rate of 1 g/kg bwt with respect to control. At the higher doses (2 & 3 g/kg) there was significant increase of total cholesterol with respect to control as shown in the Figure 1A. These results show that in a male rat significant increase in total cholesterol occur as compared

to the female rats.

The values of the total triacylglycerol levels in both male and female control rats were similar (87.71 and 85.52 mg/dL in male and female rats respectively). At the dose of 1 g/kg there was no significant change in the triacylglycerol levels in male and female rats. There was significant ($p < 0.001$) decrease in both the sexes after feeding the animals with oxidized olive oil at the dose rates of 2 & 3 g/kg bwt (Figure 1B). These results indicate similar decrease in the total triacylglycerols irrespective of the gender.

The values of HDL-cholesterol in male rats were higher than female (69.27 mg/dL of male and 63.27 mg/dL of female). Significant ($p < 0.001$) decrease was observed

in both sexes with respect to dose rates of 1, 2 and 3 g/kg bwt. These results show that female rats were more affected by decreasing the serum HDL-cholesterol levels as compared to the male rats (Figure 1C). In case of LDL-cholesterol, there was a significant difference between control male (44.93 mg/dL) and female (71.74 mg/dL) rats, which were not fed with oxidized olive oil. In male rats there was a significant ($p < 0.001$) increase with respect to increase

in the dose rates and reached a value of 134.42 mg/dL. In female rats a significant decrease occurs at the dose of 1 g/kg bwt. No significant changes at the dose of 2 g/kg, while significant ($p < 0.001$) increase occurred at the dose of 3 g/kg bwt with respect to the control (Figure 1D). These results indicate that male rats were more affected as compared to female rats with respect to the increase of doses of oxidized olive oils.

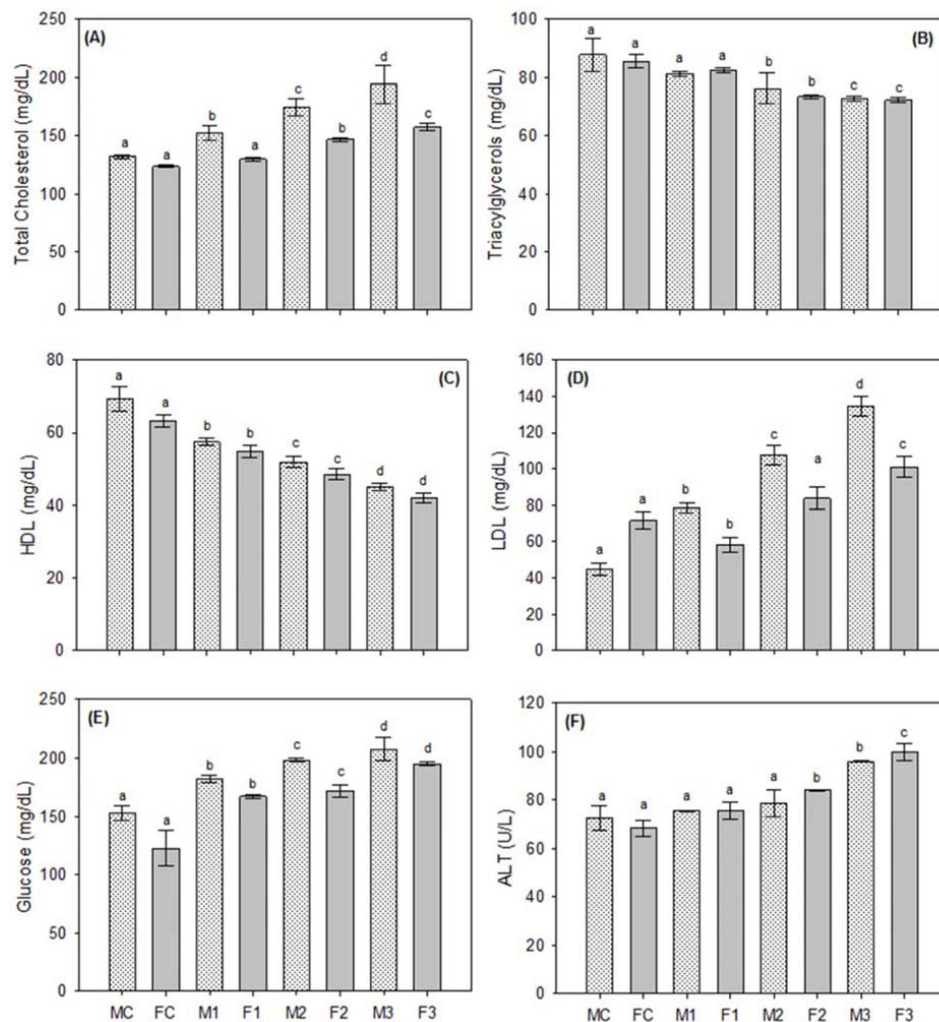


Figure 1. Effects of thermally oxidized olive oils on the serum biochemical parameters of rats, (A) Total cholesterol, (B) triacylglycerols, (C) HDL-cholesterol, (D) LDL-cholesterol, (E) Glucose, and (F) ALT. Data are means \pm SD of $n = 3$ per group. Different letters (a-d) on each male and female group represent significant at $p < 0.001$.

The glucose level was in normal reference range in both male and female control rats (152.45 and 122.59 mg/dL). In male rats, the blood glucose level increases significantly ($p < 0.001$) to 182.23, 198.39 and 207.77 mg/dL after feeding with 1, 2 and 3 g of oxidized oil, respectively. In female rats, the serum glucose was 167.02, 171.73, and 195.20 mg/dL after feeding of the respective doses of thermally oxidized oil. The increase of glucose was higher in male rats as compared to female rats. There was a significant increase ($p < 0.001$) in blood glucose level in both supplemented male and female rats as shown in Figure 1E.

The serum analysis for ALT revealed that ALT level was similar in non-treated rats (72.65 U/L in male and 68.42 U/L in female rats). There was no significant change at the dose of 1 & 2 g/kg bwt in both sexes with exception of male rats at the dose of 2 g/kg bwt. A statistically significant increase ($p < 0.001$) was observed at the dose of 3 g/kg bwt in both sexes and reached a value

of 95.92 U/L (male rats) and 100.02 U/L (female rats) (Figure 1F). These results indicate the burden of oxidized olive oil on the liver function.

3.3 Effects on Atherogenic Indices

Figure 2 shows the effects of thermally oxidized olive oil on the atherogenic indices such as cardiac risk ratio, atherosclerosis index and atherogenic index of plasma. The values of the cardiac risk ratio in both sexes were close to each other. There was significant ($p < 0.05$) increase with respect to the control rats. The increase was more pronounced in the male rats as compared to the female rats. Similarly the atherosclerosis index increase significantly ($p < 0.05$) in male rats, while the increase was less pronounced in female rats. The atherogenic index of the plasma was found to increase significantly ($p < 0.05$) with respect to treated doses. These results suggest that oxidized oils increases the atherogenic indices of the experimental animals.

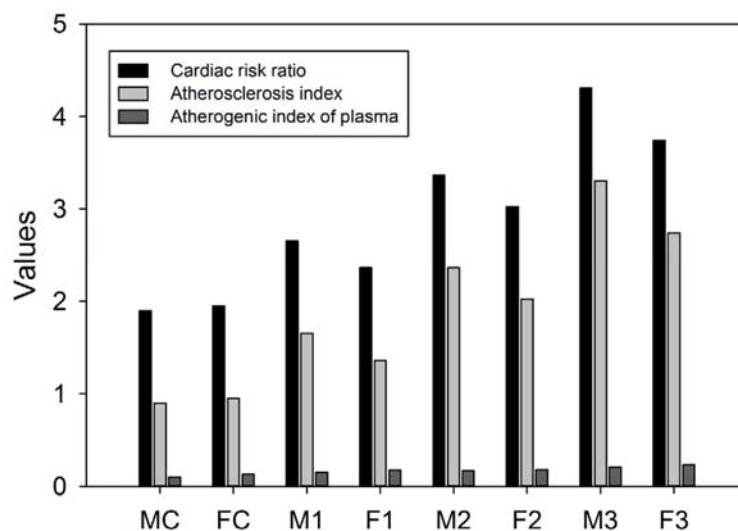


Figure 2. Effects of thermally oxidized olive oils on the atherogenic indices of rats. Data are means of triplicate ($n=3$) per group. Different letters on each male and female group represent significant at $p < 0.05$.

3.4 Effects on Haematological Parameters

The red blood cell count (RBC) in the treated groups (both male and female rats) decreases with respect to control rats ($7.7 \times 10^6/\mu\text{L}$). Female rats were more affected as compared to male as shown in the Table 2. The white blood cells (WBC) amount increases significantly ($p < 0.05$) at the higher doses as compared to control group. There was no significant change in the other treated as well as a control group. These results show the presence of inflammation or burden in the rat blood. The haemoglobin (Hb) concentration was lower in both treated male and female rats than normal un-treated control rats (14.6 % in male and 13.4 % in female). A significant ($p < 0.05$) decrease

occurs in the treated groups as compared to the control group. However, there was no significant change among the treated groups. Haematocrit (HCT) decreased in both the male and female rats as compared to un-treated control rats (45.5 % in male and 43.5 % in female). The female rats were more affected than male. The mean corpuscular volume (MCV) of the control rats was 56.1 fL in male and 51.90 fL in female groups. There was a significant ($p < 0.05$) decrease in the dose of 3 g/kg, while the decrease was not significant in other treated groups with respect to control. Similarly, there was significant ($p < 0.05$) decrease in the mean corpuscular haemoglobin concentration (MCHC) at the 3 g/kg bwt as compared to the other treated and control samples.

Table 2. Effects of supplementation of olive oil on the haematological parameters of rats.

Parameter (unit)	Treatment							
	MC	FC	M1	F1	M2	F2	M3	F3
RBC ($\times 10^6/\mu\text{L}$)	7.7 \pm 0.6	7.13 \pm 0.3	6.48 \pm 0.07	6.0 \pm 0.06	5.80 \pm 0.18	5.9 \pm 0.05	5.05 \pm 0.70	5.0 \pm 0.15
WBC ($\times 10^3/\mu\text{L}$)	9.13 \pm 0.4	8.40 \pm 0.3	9.27 \pm 0.45	9.3 \pm 0.40	10.1 \pm 0.65	10.0 \pm 0.38	11.1 \pm 0.50	11.0 \pm 0.45
Hb (%)	14.6 \pm 0.7	13.40 \pm 0.5	12.7 \pm 0.40	12.0 \pm 0.46	12.1 \pm 0.30	12.0 \pm 0.26	11.3 \pm 0.40	11.0 \pm 0.8
HCT (%)	45.5 \pm 0.4	43.50 \pm 0.6	41.7 \pm 2.0	39.0 \pm 2.0	39.7 \pm 0.60	37.0 \pm 0.25	37.1 \pm 0.26	35.0 \pm 0.16
MCV (fL)	56.1 \pm 3.3	51.90 \pm 2.2	53.6 \pm 0.83	51.1 \pm 1.2	50.9 \pm 0.75	48.0 \pm 0.95	48.5 \pm 0.55	46.0 \pm 0.40
MCH (pg)	18.0 \pm 1.0	16.00 \pm 1.0	16.7 \pm 0.57	16.0 \pm 0.58	15.0 \pm 1.0	15.0 \pm 1.0	12.3 \pm 1.15	13.0 \pm 1.0
MCHC (g/dL)	39.0 \pm 1.0	37.30 \pm 1.2	36.4 \pm 0.60	35.0 \pm 0.36	35.5 \pm 0.60	34.0 \pm 0.55	33.2 \pm 0.35	31.0 \pm 0.74
Lymphocytes (%)	71.3 \pm 4.5	75.30 \pm 2.0	77.3 \pm 2.5	76.0 \pm 2.5	84.0 \pm 1.73	83.0 \pm 3.2	87.7 \pm 3.06	91.0 \pm 2.0
PLT ($\times 10^3/\mu\text{L}$)	304.0 \pm 11	290.0 \pm 7.5	357 \pm 9.6	365.0 \pm 8.7	402.0 \pm 9.0	392.0 \pm 5.5	466.0 \pm 10.8	445.0 \pm 6.5

Values are expressed as Mean \pm SD of $n=3$ or otherwise mentioned. RBC, red blood cells; Hb, hemoglobin; HCT, hematocrit; MCV, mean corpuscular volume; MCH, mean corpuscular hemoglobin; MCHC, mean corpuscular hemoglobin concentration; WBC, white blood cells; PLT, platelets.

Lymphocyte count was in normal range (71.3 % and 75.3 %) in both male and female control rats as shown in table 2. In male rats fed with oxidized olive oil at a dose rate of 1, 2 and 3 g/kg bwt, the lymphocyte count was 77.3, 84.0, and 87.7 % respectively. In female rats, the lymphocyte count was 76.0, 83.0 and 91.0% for groups with 1, 2 and 3 g/kg bwt respectively. These results showed that there was a significant increase ($p < 0.05$) in the group which was supplemented with 3 g/kg bwt of oxidized olive oil. In both the normal male and female rats, the platelet count was in a similar range as shown in the table 2. In male rats, the platelets count increases significantly ($p < 0.05$) to $357.0 \times 10^3/\mu\text{L}$, $402.0 \times 10^3/\mu\text{L}$, and $466.0 \times 10^3/\mu\text{L}$ for the doses of 1, 2 and 3 g/kg bwt respectively. Similarly, in female rats, the significant ($p < 0.05$) increase reached to $365 \times 10^3/\mu\text{L}$ (1 g/kg bwt), $392 \times 10^3/\mu\text{L}$ (2 g/kg bwt) and $445 \times 10^3/\mu\text{L}$ (3 g/kg bwt) at the end of treatments.

3.5 Effects on Liver Histology

The changes in biochemical and haematological parameters were further confirmed by a comparative histo-

pathological examination of the liver sections from rats fed on oxidized olive oil as well as normal olive oil. Figure 3A shows normal liver of the control male rats showing normal morphology. Similar results were also observed in case of control female rats. Figure 3B shows the liver of male rats (M1) with central veins showing normal endothelial linings with no evidences of fibrosis. The hepatic cords are well formed with intervening sinusoids extending from portal tracts to the central vein. The hepatocytes show mild micro vesicular fatty changes. The fatty change is relatively more prominent around the central veins and show a progressive decrease towards portal tracts. Kupffer cells are slightly larger and appear reactive. Similar results were also observed for F1 group. Figure 3C shows the liver of male rats showing similar morphology to M1. There is a mild mid zonal micro-vesicular fatty change. Kupffer cells are slightly larger and appear reactive. No bile plugs in canaliculi with no intracellular cholestasis and having no fibrosis around sinusoids. There is mild infiltration of lymphocytes. Similar results were observed for F2 group.

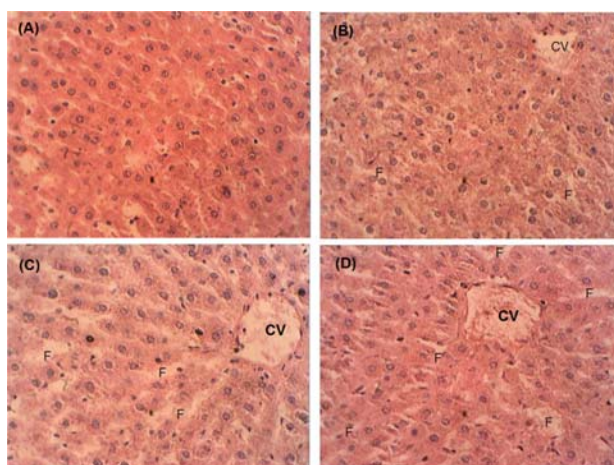


Figure 3: Effects of thermally oxidized olive oils on the liver histo-pathology of rats, (A) Normal rat liver (M), (B) M1, (C) M2 and (D) M3. The photograph was taken with 40 X electronic binocular microscope. CV is central vein and F is fat generated is highly visible.

Figure 3D shows the liver of male rats (M3) showing fatty changes. In this case the central veins showed normal endothelial linings with no evidences of pericentral fibrosis. The hepatocytes show micro-vesicular fatty changes. The fatty change is relatively more prominent around the mid zone area. Similarly Kupffer's cells were slightly larger and were reactive. The portal tract showing branches of hepatic artery, portal vein and cholangioles with normal morphology. There is mild infiltration of lymphocytes. Similar observations were recorded for F3 group. These results showed that supplementation of thermally oxidized olive oil is one of the main reasons for fatty liver development in the experimental animals.

4. DISCUSSION

Olive oil is used as main dietary oil in the Mediterranean region as well as across the globe [1]. However, continuous cooking using olive oil results in the formation of hydroperoxides and other oxidation compounds which produce several detrimental effects on upon ingestion [4, 17]. During thermal oxidation, several naturally occurring antioxidants are destroyed. In this study olive oil was thermally oxidized, which resulted in the significant decrease in the total phenolic compounds. These results are in agreement with results of Gutierrez et al. [18] who showed a significant decrease of total phenolic contents upon thermal oxidation in the Rancimat at 100 °C. Thus, it was confirmed that upon oxidation TPC decreases significantly irrespective of the types of oxidation. In addition to this, the major components such as triacylglycerol, which are made of fatty acids, among which oleic acid is major one are oxidized to form primary oxidation products. The primary oxidation products degraded with

the subsequent oxidation produces secondary oxidation products as shown in the table 1, which are usually highly reactive and thus increase the reactive oxygen activity in the body. The antioxidant potential of oxidized oil is reduced as shown by the RSA value of the oils. It was found that RSA values decreases significantly with oxidation.

The oxidized oils upon ingestion increase the serum total cholesterol, LDL-cholesterol, glucose and ALT levels of the rats, while triacylglycerol and HDL-cholesterol decreased significantly. Similar observations were reported for the supplementation of thermally oxidized vanaspati ghee to the rabbits [13]. Our results are in agreement with a recent study, which also showed that thermally oxidized sunflower oil increases the serum total cholesterol and LDL-cholesterols, while decreased HDL-cholesterol [19]. It is therefore concluded that thermally oxidized oil when fed to the rabbits, rats or other animals produce similar results irrespective of the type of edible oil. However, thermally oxidized tallow [20], vanaspati ghee [21] or edible oils oxidized at relatively high temperature produced highly toxic effects as compared to thermally oxidized olive oil.

To the best of our knowledge, this is the first study to determine the atherogenic indices of the thermally oxidized treated olive oils rats (both male & female). For this purpose, commercial virgin olive oil was thermally oxidized at 100 °C and fed to the rats. Serum lipid profile and reactive oxygen species play a significant role in the development atherosclerosis [22]. Thermally oxidized olive oil was found to significantly enhance the atherogenic indices. The cardiac risk ratio increases with increase of oxidized olive oil doses. The increase in the LDL-cholesterol can contribute to the formation of oxidized LDL, which may be present in the arterial lesions and thus contribute to the

increase in the cardiac risk ratio. Similarly the increase in the atherosclerosis index and atherogenic index of plasma can be attributed to the increase in the LDL-cholesterol. From this study, we proposed that oxidized triacylglycerols upon ingestion enters chylomicrons in the intestine. Within the chylomicrons oxidized triacylglycerols are inter-converted to oxidized phospholipids. These oxidized phospholipids and oxidized triacylglycerols are taken up by LDL and become oxidized LDL. The oxidized LDL when reached liver, they are not metabolized or metabolism of oxidized LDL or lipids becomes slow due to the increase in the reactive oxygen species. Thus are contributing to the development of fatty liver as well as atherogenesis [23]. This is evident from the Figure 3, which shows fatty infiltration in the liver.

Our results are in agreement with histological findings of Gabriel et al. [8, 24]. The authors fed thermally oxidized oils to the rats along with normal diet. They observed atrophy of the hepatic cords and pyknosis of many nuclei. Sinusoids were moderately dilated. The endothelial and Kupffer cells were highly prominent than normal. The resultant fatty liver increases the value of serum liver function enzymes.

5. CONCLUSIONS

In conclusion, rats behave differently to the different doses of oxidized olive oil. The most affected by the oxidized lipids was male rats as compared to the female rats. Oxidized oils contributed significantly to the development of atherogenesis, produce toxic properties in terms of biochemical and physiological parameters and fatty liver in rats. Based on these findings, it is suggested that in order to avoid the toxicity and negative effects of oxidized oils, a supplement remedy should be used along with the oxidized oils.

ACKNOWLEDGEMENT

The work is kindly supported by the Higher Education Commission (HEC) Pakistan under National Research Program for Universities (project no. 2344). Authors have no conflict of interest to any person or anybody.

AUTHORS CONTRIBUTIONS

AAK & AZ designed and carried out the experiments. STHS carried out GC-MS analysis. AZ wrote the paper, while STHS reviewed and contributed to the final version of this manuscript. All authors contributed equally and approved the final manuscript.

REFERENCES

- [1] Zeb A. and Murkovic M., Olive (*Olea europaea* L.) Seeds, From Chemistry to Health Benefits; in Preedy V.R. Watson R.R. and Patel V.B., eds., *Nuts and Seed in Health and Diseases Prevention*, Academic Press, London, 2011: 847-853. DOI 10.1016/B978-0-12-375688-6.10100-8.
- [2] Flores M.I.A., Romero-Gonzalez R., Garrido Frenich A. and Martinez-Vidal J.L., *Food Chem.*, 2012; **134**: 2465-2472. DOI 10.1016/j.foodchem.2012. 04.058.
- [3] Ollivier D., Artaud J., Pinatel C., Durbec J.P. and Guerere M., *J. Agric. Food Chem.*, 2003; **51**: 5723-5731. DOI 10.1021/jf034365p.
- [4] Zeb A. and Murkovic M., *Food Chem.*, 2011; **127**: 1584-1593. DOI 10.1016/j.foodchem.2011.02.022.
- [5] Lipworth L., Martinez M.E., Angell J., Hsieh C.C. and Trichopoulos D., *Prev. Med.*, 1997; **26**: 181-190. DOI 10.1006/pmed. 1996.9977.
- [6] Manna C., Galletti P., Cucciolla V., Montedoro G. and Zappia V., *J. Nutr. Biochem.*, 1999; **10**: 159-165. DOI 10.1016/S0955-2863(98)00085-0.

- [7] Farras M., Valls R.M., Fernandez-Castillejo S., Giralt M., Sola R., Subirana I., Motilva M.J., Konstantinidou V., Covas M.I. and Fito M., *J. Nutr. Biochem.*, 2013; **24**: 1334-1339. DOI 10.1016/j.jnutbio.2012.10.008.
- [8] Gabriel H.G., Alexander J.C. and Valli V.E., *Lipids*, 1978; **13**: 49-55. DOI 10.1007/BF02533366.
- [9] Bird R.P. and Alexander J.C., *Lipids*, 1979; **14**: 836-841. DOI 10.1007/BF02534125.
- [10] Firestone D., *Official Methods and Recommended Practices of the American Oil Chemists' Society*, AOCS Press, Champaign, 1998.
- [11] Slinkard K. and Singleton V.L., *Am. J. Enol. Vitic.*, 1977; **28**: 49-55.
- [12] Zeb A., *Afr. J. Biotechnol.*, 2011; **10**: 15346-15352.
- [13] Zeb A. and Mehmood A., *Turk. J. Biochem.*, 2012; **37**: 417-423. DOI 10.5505/tjb.2012.63325.
- [14] Friedewald W.T., Levy R.I. and Fredrickson D.S., *Clin. Chem.*, 1972; **18**: 499-502.
- [15] Ikwuchi J.C., Onyeike E.N., Uwakwe A.A. and Ikwuchi C.C., *J. Ethnopharmacol.*, 2011; **137**: 1415-1424. DOI 10.1016/j.jep.2011.08.015.
- [16] Kondou H., Mushiake S., Etani Y., Miyoshi Y., Michigami T. and Ozono K., *J. Hepatol.*, 2003; **39**: 742-748.
- [17] Zeb A., *Free Rad. Res.*, 2015; **49**: 549-564. DOI 10.3109/10715762.2015.1022540.
- [18] Gutierrez F., Villafranca M.J. and Castellano J.M., *J. Am. Oil Chem. Soc.*, 2002; **79**: 669-676. DOI 10.1007/s11746-002-0541-3.
- [19] Zeb A. and Hussain H., *J. Food Biochem.*, 2014; **38**: 498-508. DOI 10.1111/jfbc.12082.
- [20] Zeb A. and Rahman W., *Toxicol. Res.*, 2012; **28**: 151-157. DOI 10.5487/TR.2012.28.3.151.
- [21] Zeb A. and Ullah S., *Food Chem.*, 2015; **186**: 6-12. DOI 10.1016/j.foodchem.2015.03.053.
- [22] Chisolm G.M. and Steinberg D., *Free Rad. Biol. Med.*, 2000; **28**: 1815-1826. DOI 10.1016/S0891-5849(00)00344-0.
- [23] Eckl P.M., Ortner A. and Esterbauer H., *Mut. Res.*, 1993; **290**: 183-192.
- [24] Gabriel H.G., Alexander J.C. and Valli V.E., *Can. J. Comp. Med.*, 1977; **41**: 98-106.