

# Enteric Fever-like Illness Caused by Infection with *Citrobacter Amalonaticus*

Kanitta Suwansrinon, MD\*, Henry Wilde, MD\*,  
Visith Sitprija, MD\*, Rekha Hanvesakul, MD\*\*

\* *Queen Saovabha Memorial Institute, Thai Red Cross Society  
(WHO Collaborating Center for Research in Rabies)*

\*\* *BNH Hospital, Convent Rd, Silom*

---

*'Enteric fever' is a potentially fatal, severe systemic disease, which is encountered worldwide. Traditionally, enteric fever refers to a bacteremic illness caused by members of certain Salmonella serotypes, notably: Salmonella typhi, a Gram-negative bacterium, and to a lesser extent, Salmonella paratyphi A, B and C. In addition, other non-salmonella organisms may produce a syndrome clinically indistinguishable from "enteric fever". Brucella sp., Campylobacter sp., Edwardsiella tarda, Enterobacter Cloacae, Escherichia coli, Klebsiella pneumoniae, Providencia alcalifaciens, Pseudomonas sp., Serratia marcescens, Francisella sp. and Yersinia pp have been identified in enteric fever. This is, to the best of the authors' knowledge, the first case of Citrobacter to be reported presenting as enteric fever in a normal host in Thailand.*

**Keywords:** Enteric fever, *Citrobacter sp.*

**J Med Assoc Thai 2005; 88(6): 837-40**

**Full text. e-Journal:** <http://www.medassochai.org/journal>

---

'Enteric fever' is a serious systemic disease caused by an organism that is spread principally via the oro-fecal route. Not all patients develop the classic features of acute febrile illness of prolonged duration with gradual than hectic rise of fever, bacteremia, delirium, abdominal pain and a wide accompaniment of systemic manifestations. Pathologically, it is a unique illness on the basis of its association with enlarged Payer's patches and mesenteric lymphadenopathy<sup>(1)</sup>.

Initial symptoms typically include fever, anorexia, lethargy, malaise, dull continuous headache, non-productive cough and vague abdominal pain. Vomiting and diarrhea are typically absent and constipation is frequently reported<sup>(2)</sup>. Enteric fever is a systemic illness where blood cultures are more likely to be positive than stool cultures. Despite high fever, the pulse is often only slightly elevated and this is known as pulse-temperature discrepancy. After the first week, some patients develop a maculopapular

rash (rose spot) on the upper abdomen. These are more often identified in Caucasian subjects. During the second week of the illness, protracted fever and mental dullness commonly appear. Many patients develop mild hepatosplenomegaly and as many as 10% of untreated infections may be fatal. Relapses are not uncommon and usually respond to the same antibiotics used in the primary manifestation<sup>(3)</sup>. Complications occur mostly in untreated patients. They are gastrointestinal perforation or hemorrhage, cholecystitis (often alcoholic cholecystitis), myocarditis, meningitis, encephalopathy or focal abscess<sup>(4)</sup>.

Enteric fever most frequently reported is caused by *Salmonella typhi* or, to a lesser extent, *Salmonella paratyphi*. Although other non-salmonella organisms may clinically and pathophysiologically qualify as potentially capable of inducing the enteric fever syndrome. *Brucella sp.*, *Campylobacter sp.*, *Edwardsiella tarda*, *Enterobacter Cloacae*, *Escherichia coli*, *Klebsiella pneumoniae*, *Providencia alcalifaciens*, *Pseudomonas sp.*, *Serratia marcescens*, *Francisella sp.* and *Yersinia sp.* have been identified, though less commonly than *Salmonellae*<sup>(5)</sup>. The cases of normal hosts in whom *Citrobacter freundii*, caused a primary

---

Correspondence to : Suwansrinon K, Queen Saovabha Memorial Institute, Thai Red Cross Society, 1871 Rama IV Rd, Bangkok, 10330, Thailand. Phone: 0-2252-0161 ext. 166, 0-6300-6308, Fax: 0-2254-0212, E-mail: [sukanitta@yahoo.com](mailto:sukanitta@yahoo.com)

invasive illness similar to typhoid fever, have been reported<sup>(6)</sup>. Presumably, all these organisms are able to live and multiply within macrophages by preventing phagolysosomal fusion. Being inside the macrophages, prevents the bacteria from being destroyed by PMNs and the complement system. They then disseminate throughout the body in macrophages via lymphatics and colonize macrophages of the liver, gallbladder, spleen, lymph nodes, lung, bone, and other organs<sup>(7)</sup>.

The authors have not been able to find a reported case of enteric fever due to *Citrobacter amalonaticus*. They are gram-negative rods belonging to the Enterobacteriaceae family which contains 11 named different species, by using the recommended definition of a genomospecies<sup>(8)</sup>: *C. amalonaticus*, *C. braakii*, *C. farmeri*, *C. freundii*, *C. gillennii*, *C. koseri* (*C. diversus*), *C. murlinae*, *C. rodentium*, *C. sedlakii*, *C. werkmanii* and *C. youngae*<sup>(9)</sup>. These organisms are closely related to the Salmonellae.

*Citrobacter* sp. presents a challenging therapeutic problem, especially as nosocomial infection. They may be mistaken as contaminants since they are frequently present in humans as normal intestinal inhabitants. The spectrum of disease due to *Citrobacter* sp. includes bacteremia/sepsis, bone and joint infection, lung abscess, omphalitis, urinary tract infection, respiratory tract infection and endocarditis<sup>(10,11)</sup>. *Citrobacter* sp. may be recovered from blood cultures in association with a known focus of infection, or may be present as primary bacteremia with no clear source<sup>(12)</sup>. *Citrobacter* bacteremia most commonly occurs in patients with malignancies or hepatobiliary stones. The mortality associated with *Citrobacter* bacteremia was approximately 18%. Poor prognostic factors include pneumonia, altered mental status on presentation, hypothermia, oliguria, septic shock, deterioration in mental status, hyperbilirubinemia, azotemia, and thrombocytopenia. Appropriate antibiotic therapy improved the outcome of *Citrobacter* bacteremia<sup>(13)</sup>.

Prevention of infection with pathogenic strains should focus on personal hygiene, proper sewage treatment, hand washing prior to food handling, pasteurization of milk, proper cooking of eggs, poultry, and other meats<sup>(14,15)</sup>.

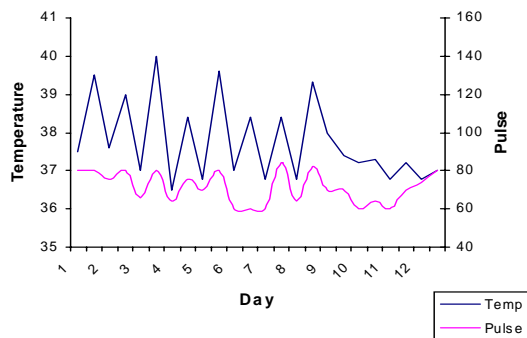
### Case Report

A 53-year-old American male tourist presented with a high fever for 4 days before admission. His temperature was 38.4 °C accompanied with watery

diarrhea 4-5 times per day and severe headaches. The patient had been traveling through Asia for the past 10 months and had watery diarrhea off and on most of the time. He had had a colonoscopy done last year in the United States and the results of the test were unremarkable. Although diarrhea had resolved completely at that time, it resumed earlier this year when he resumed his Asian travel. His past history was entirely unremarkable.

On physical examination, the patient appeared tired, pale, and dehydrated with a temperature of 38.4 °C, a pulse rate of 80 per minute, a respiratory rate of 20 per minute, and blood pressure of 120/80 mmHg. He was well nourished and looked physically fit. His general examination was unremarkable.

Laboratory investigations revealed the following, Hemoglobin 13.5 g/dL, white blood cell count 3,930/mm<sup>3</sup> (N69%, L17%, E11% with atypical lymphocytes 3%), platelet 230,000/mm<sup>3</sup>, AST 455 U/L, ALT 497 U/L and Alkaline Phosphatase 521 U/L. Several stool examinations revealed watery stools, no parasites or white blood cells were seen. Stool cultures revealed no pathogenic organisms. Blood films for malaria, HIV ELISA test, and chest radiograph were normal. An initial blood culture revealed *Citrobacter* sp. resistant to ampicillin, MIC co-trimoxazole 0.19 ug/ml, ceftriaxone 0.38ug/ml, levofloxacin 0.50ug/ml. The organism was first considered a contaminant and cultures were repeated twice revealing the same organism. This was confirmed by a second academic laboratory. The biochemical reaction of cultures were compared to Bergey' manual<sup>(16)</sup> and found consistent at 97% with *Citrobacter amalonaticus*. The diagnosis of an "enteric fever syndrome" due to *Citrobacter amalonaticus* was then made and the patient was started on intravenous ceftriaxone 2g every 12 hours. His diarrhea improved. However, his fever persisted for 6 days after antibiotic therapy and he still experienced severe headaches. CT scan of the abdomen and an upper GI series with small bowel follow through was then performed. The results of both tests were normal. Spleen sizes on CT were normal. After nine days of ceftriaxone, oral co-trimoxazole was added on day 10 but the following day his fever subsided and he began to feel better. The intravenous ceftriaxone was then discontinued and he was maintained on oral co-trimoxazole. Repeat blood cultures were negative and liver function tests started normalizing. He was asked to continue oral co-trimoxazole (2 tablets twice daily) for an additional 2 weeks and was discharged. He remained well when followed for a week



as an outpatient. This is a figure showing the patient's temperature and pulse curve:

## Discussion

The presented patient presented as a case of fever, watery diarrhea and headache without any other organ-specific symptoms or findings, which persisted for nearly 2 weeks. The initial blood culture raised skepticism as the authors expected to find *Salmonellae* as cause and first suspected *Citrobacter* to be a contaminant in the initial single blood sample. The presented case is, to the best of the authors' knowledge, the first to describe a normal host presenting with the enteric fever syndrome due to *Citrobacter amalonaticus* and only the second one with any member of the *Citrobacter* family<sup>(6)</sup>. The enteric fever syndrome is well known for the rather lengthy persistence of fever and headaches after starting appropriate antibiotic therapy. Fever rarely disappears before 5-6 days and inpatient attending physicians often add a second antibiotic or even change drugs by day 5 or 6. This, indeed, also happened in the present case when co-trimoxazole was added on day 6. Good techniques of specimen collection, awareness by the clinician, and clear communication with the microbiologist are essential for proper identification and interpretation of blood culture results.

*Citrobacter* is common in the environment and may be spread by person-to-person contact. Several outbreaks have occurred in babies in hospital units<sup>(17)</sup>. It can be isolated from water, fish, animals and food<sup>(18)</sup> and is considered an opportunistic pathogen. It can also be found in the gut as part of the normal flora<sup>(19)</sup>. *Citrobacter*, like *Salmonella*, produces secretory enterotoxins that act on intestinal mucosa and cause abnormal fluid secretion<sup>(20)</sup>. However, the pathogenesis of *Citrobacter* infection presenting as enteric fever syndrome is not known. The radiologist

was unable to identify Payer's patch hypertrophy on the small bowel series and CT scan of the present case.

Although this condition is quite rare, it is an important entity due to increased frequent infections in travelers, and the frequent occurrence of *Citrobacter* sp. sepsis in patients with acquired immunodeficiency syndrome<sup>(21)</sup>. Enteric fever due to non-salmonella organisms should be kept in mind, particularly, in patients with recent travel to developing regions. Enteric fever should not be as closely identified with *Salmonellae*, as is commonly the case. It is better thought of as a 'syndrome' induced by many organisms.

## Acknowledgement

The authors wish to thank Dr. Wanla Kulwichit, Chulalongkorn University, Bangkok, for his generous help.

## References

1. Fauci B, Hauser K, Jameson L. Harrison's principles of internal medicine, 16<sup>th</sup> edition, 2005, Chapter 200.
2. Lakhota M, Gehlot RS, Jain P, Sharma S, Bhargava A. Neurological manifestations of enteric fever. *JACM* 2003; 4: 196-9.
3. Oregon Health Services, Investigative Guidelines, October 2002.
4. Parry CM, Hien TT, Dougan G, White NJ, Farrar JJ. Typhoid fever: *N Engl J Med* 2002; 347: 1770-82.
5. Moodley P. Course module. University of Kwazulu-Natal, 15 November 2004.
6. Flegg PJ, Mandal BK. *Citrobacter freundii* bacteraemia presenting as typhoid fever. *J Infect* 1989; 18: 171-3.
7. Uzzau S, Brown DJ, Wallis T, Rubino S, Leori G, Bernard S, et al. Host adapted serotypes of *Salmonella enterica*. *Epidemiol Infect* 2000; 125: 229-55
8. Brenner DJ, Grimont PA, Steigerwalt AG, Fanning GR, Ageron E, Riddle CF. Classification of *Citrobacter* by DNA hybridization: designation of *Citrobacter farmeri* sp. Nov., *Citrobacter youngae* sp. Nov., *Citrobacter braakii* sp. Nov., *Citrobacter werkmanii* sp. Nov., *Citrobacter sedlakii* sp. Nov., and three unnamed *Citrobacter* genomospecies: *Int J Syst Bacteriol* 1993; 43: 645-58.
9. DSMZ. Genus *CITROBACTER*, Bacterial Nomenclature Up-to-Date, 2003.
10. Williams LK, Medical Evaluation and Risk Assessment Unit, North Carolina Department of Health and Human Services. Microorganisms That May Be Found In Drinking Water.
11. Lipsky BA, Hook EW III, Smith AA, Plorde JJ. *Citrobacter* infections in humans, experience at the Seattle Veterans Administration Medical Center and

- a review of the literature. Rev Infect Dis 1980; 2: 746-60.
12. Gupta N, Yadav A, Choudhary U, Arora DR. Citrobacter bacteremia in a tertiary care hospital. Scand J Infect Dis 35, case reports, 2003: 765-8.
  13. Shih CC, Chen YC, Chang SC, Luh KT, Hsieh WC. Bacteremia due to Citrobacter species: significance of primary intraabdominal infection. Clin Infect Dis 1996; 23: 543-9.
  14. Levine MM. Typhoid fever. In: Evans AS, Brachman PS, eds. Bacterial Infections of Humans, Epidemiology and Control. Third edn. New York: Plenum Medical Book Company, 1998: 839-58.
  15. Street foods made safe. News & highlights, United Nations' Food and Agricultural Organization (FAO), August 21, 2001.
  16. Holt JG, Krieg NR, Sneath PHA, Staley JT, Williams ST. Bergey's Manual of determinative bacteriology, Ninth edition. Baltimore: Williams and Wilkins, 1994
  17. Abbott S. Klebsiella, Enterobacter, Citrobacter, and Serratia, In: Murray PR, Baron EJ, Pfaller MA, Tenover FC, Tenover RH, eds. Manual of Clinical Microbiology. 7<sup>th</sup> ed. Washington DC: ASM Press; 1999: 478.
  18. Varnum AH, Evans MG. Foodborne Pathogens: An Illustrated Text. St Louis: Mosby Year Book, 1991: 357.
  19. Rowe B, Gross RJ, Allen HA. Citrobacter koseri, II. Serological and biochemical examination of Citrobacter koseri strains from clinical specimen: J Hyg (Lond), 1975; 75: 129-34.
  20. Clinical Microbiology Topics. Diarrheal infectious diseases. 2004: 1-5.
  21. Cohen JI, Bartlett JA, Corey GR. Extra-intestinal manifestations of salmonella infections. Medicine (Baltimore) 1987; 66: 349-88.

---

### Enteric fever-like illness ที่เกิดจาก *Citrobacter amalonaticus*

ชนิษฐา สุวรรณศรีนนท์, เฮนรี ไวลด์, เรขา หาญเวสสะกุล, วิศิษฎ์ สิตปรีชา

*Enteric fever* เป็นโรคติดเชื้อทางกระแสเลือดที่ทำให้เสียชีวิตได้ เป็นปัญหาสำคัญทั่วโลก โดยทั่วไป *enteric fever* คือการติดเชื้อแบคทีเรียในกระแสเลือดซึ่งเกิดจาก เชื้อ *Salmonella typhi* เป็นส่วนใหญ่ และที่พบรองลงมาคือ เกิดจากเชื้อ *Salmonella paratyphi A, B* และ *C* และยังพบว่า นอกจากเชื้อ *Salmonella* ยังมีเชื้ออื่น ๆ ที่สามารถทำให้เกิด *enteric fever syndrome* ได้ ดังเช่นเชื้อ *Brucella sp.*, *Campylobacter sp.*, *Edwardsiella tarda*, *Enterobacter Cloacae*, *Escherichia coli*, *Klebsiella pneumoniae*, *Providencia alcalifaciens*, *Pseudomonas sp.*, *Serratia marcescens*, *Francisella sp.* และ *Yersinia sp.* เป็นการรายงานครั้งแรกในประเทศไทยของ เชื้อ *Citrobacter* ที่ทำให้เกิด *enteric fever* และเป็นรายงานครั้งแรกของเชื้อ *Citrobacter amalonaticus*

---